



Nightingale Research Foundation

www.nightingale.ca

121 Iona Street
Ottawa, Canada
K1Y 3M1

Improving Patient's Lives with Multi-System Disease

The Academy of Nutritional Medicine (AONM)

My appreciation to:
The Academy of Nutritional Medicine
(AONM)
&
Clare Palmer and Gilian Crowther

Dr John Richardson at 80 years, stepping down from his Tiger Moth WWI fighter plane.

Dr. John Richardson M.B., B.S.



Reproduction by Golden Lang Colour Laboratories, photo retouching by John Evans Photography Ltd.

- Dr Richardson, a country GP from Newcastle UK, was one of those responsible for kindling my interest in M.E.
- He followed M.E. patients for up to 4 generations & demonstrated genetic & physical factors governing illness of M.E. patients.

Questions?

Can we have a show of hands?

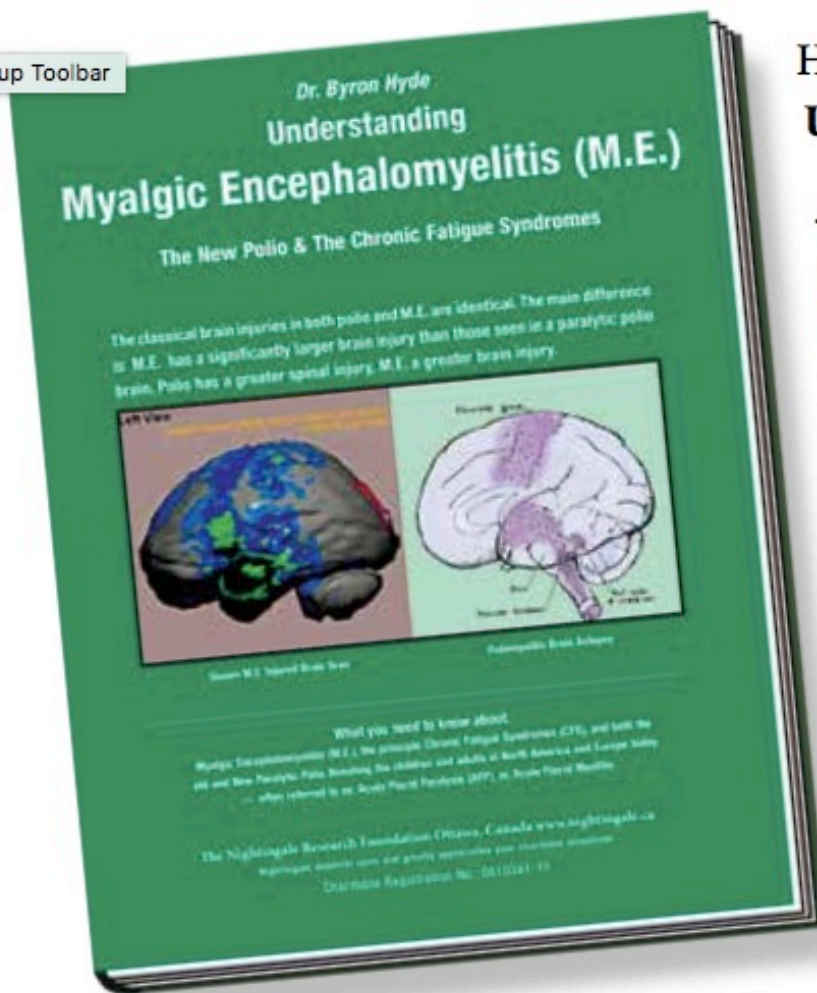
1. Who here has or knows someone with M.E.?
2. How to you test for M.E.?

Questions?

Can we have a show of hands?

1. Who here has or knows someone with M.E.?
2. How to you test for M.E.?

Show Markup Toolbar



Here is a sample of what you will find in **Understanding Myalgic Encephalomyelitis:**

-In 1914, William Osler, probably Canada's most famous physician, precisely described M.E. It was then called Neurasthenia.

William Osler's 1914 Description of M.E.

M.E. (neurasthenia) is neither a psychiatric nor a genetic disease. It is due to either an infection or toxic exposure.

*M.E. (Neurasthenia) **should not be confused with hysteria or anxiety** and has to be diagnosed from the patient's statements rather from the physical examination.*

Questions?

1. Who here knows why most doctors in the UK believe M.E. is a form of hysteria & treat M.E. patients as though they were nut cases?



Los Angeles County General Hospital Epidemic 1934

Hospital Settlement 1939

In today's funds: The insurance industry paid to each of the medical staff ill with M.E.
5 million pounds sterling
in US dollars.

Dr Colin McEvedy Magdalen College Oxford & his tutor, Dr. Alfred William Beard



In 1969, Colin McEvedy asked Dr Melvin Ramsay if he could examine the files of the 1955-57 Royal Free Hospital epidemic 292 patients. Ramsay agreed & took him to the files. Less than two hours later, Ramsay returned, and McEvedy has already left, never to return.

Dr Colin McEvedy's Oxford, PhD Thesis

Their thesis stated the Royal Free Epidemic was a case of Mass Hysteria.

- 1: a enormously long and detailed set of statistics I believe are only available to the insurance industry.
- 2: Immediately this was printed in USA in Time magazine.
- 3: Ever since doctors are ashamed to consider M.E. patients have anything but a psychiatric or anxiety or hysteria.

Dr. Alfred William Beard

Expert for insurance company

In a case heard before Justice McPherson on June 26, 1989, the patient's lawyer, Mr Beckman, asked psychiatrist Alfred Beard, who had given a psychiatric diagnosis to a patient:

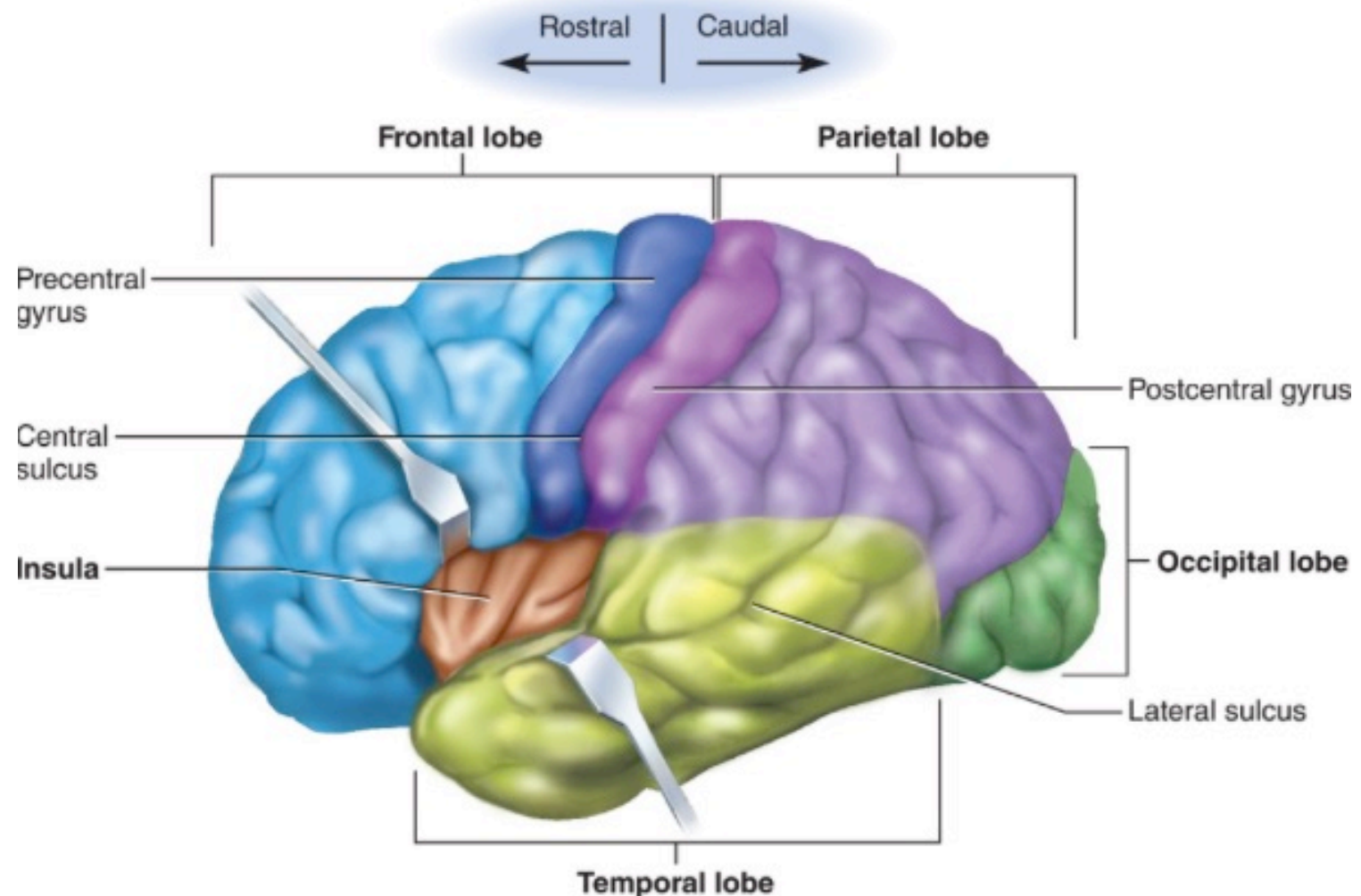
“ Did you examine the patient?”

Dr. Beard answered:

“A psychiatrist does not ordinarily conduct a physical examination.”

The 5 Brain Lobes

Copyright © McGraw-Hill Education. Permission required for reproduction or display.



HOMEOSTASIS, POTS, DYSAUTONOMIA

Postural Orthostatic Tachycardia Syndrome
Maintaining normal BP on movement

Questions?

Can we have a show of hands?

1. Who here knows how to test for M.E.?

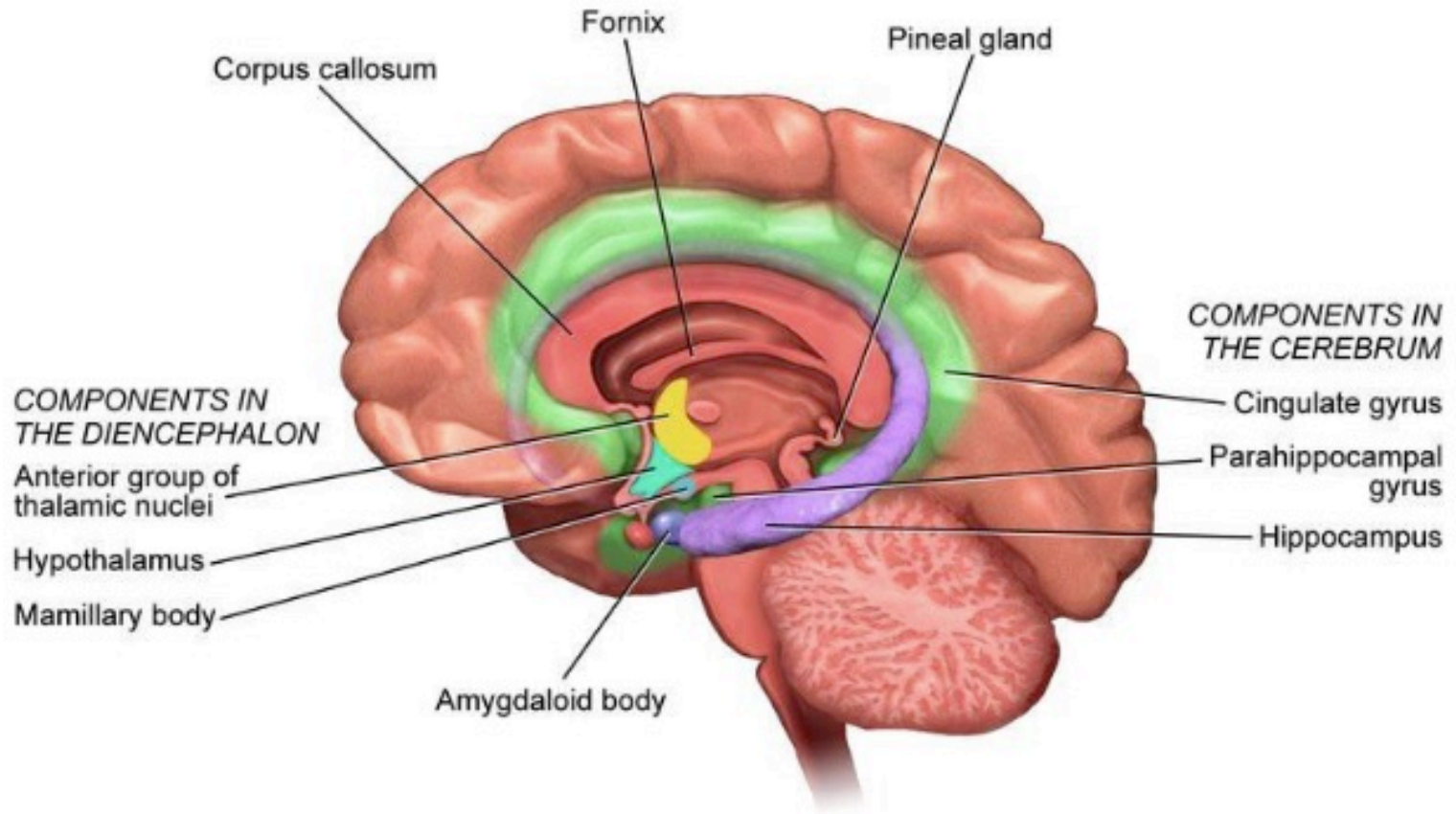
Questions?

Can we have a show of hands?

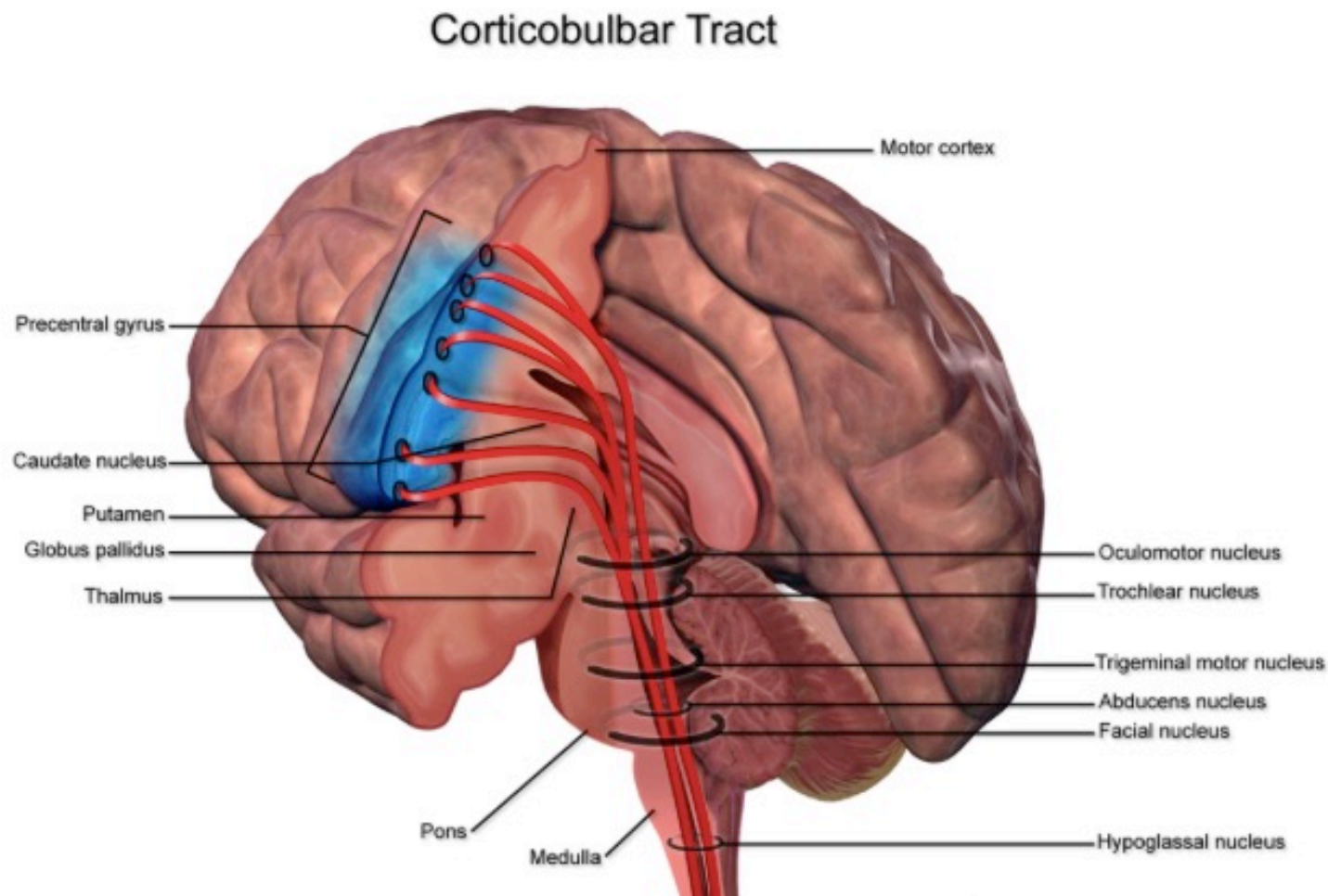
1. Who here knows what Segami oasis is?

The Cingulate Gyrus of the Limbic System

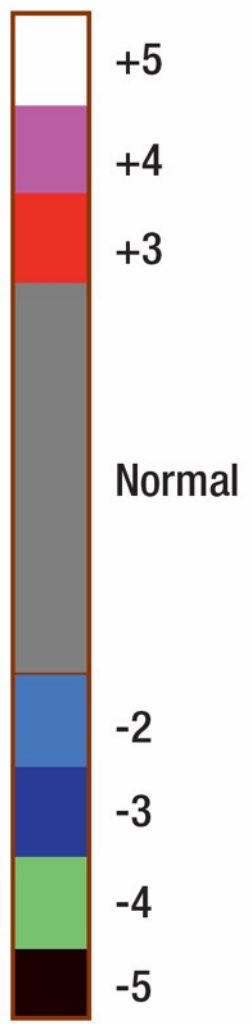The Limbic System



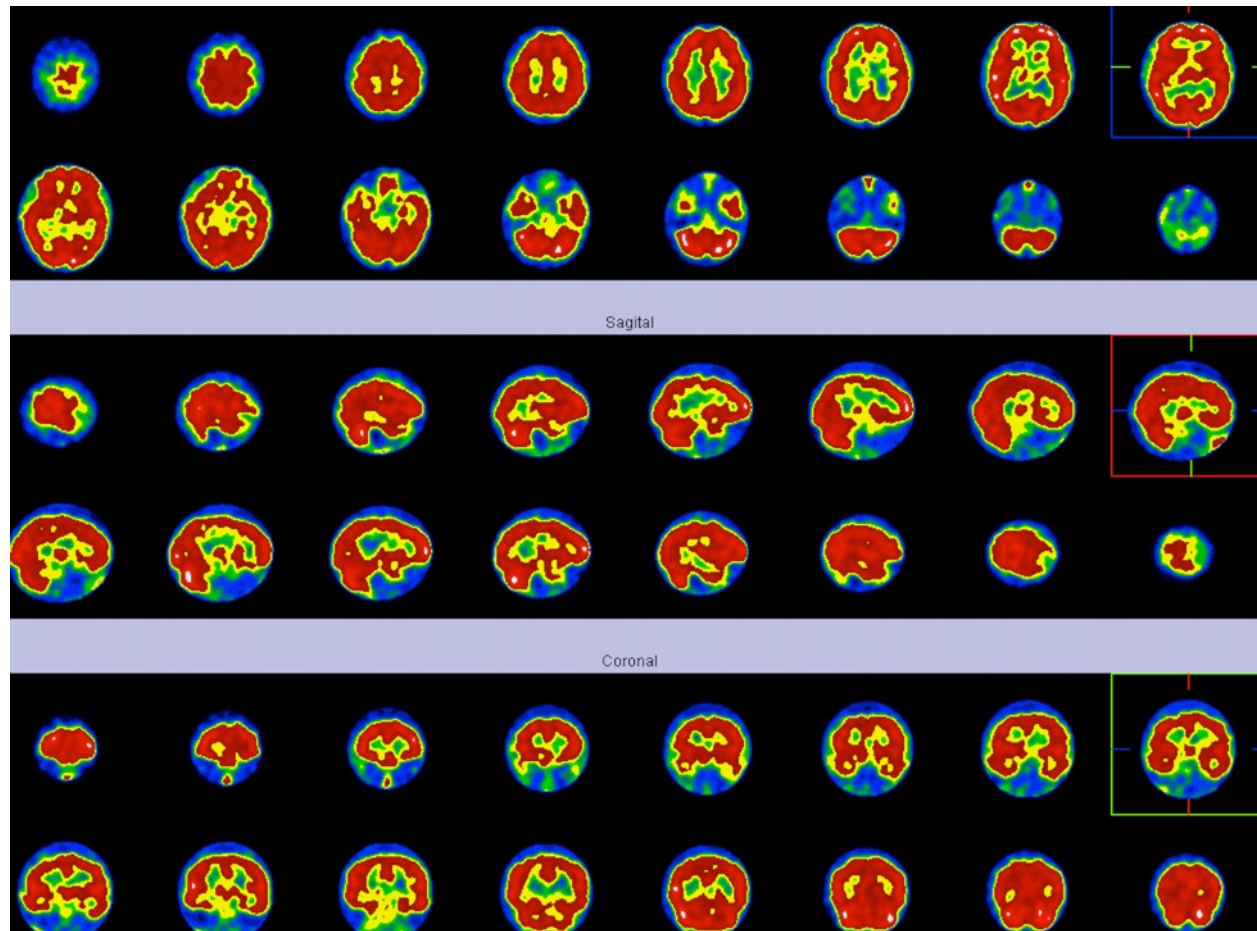
Motor Cortex



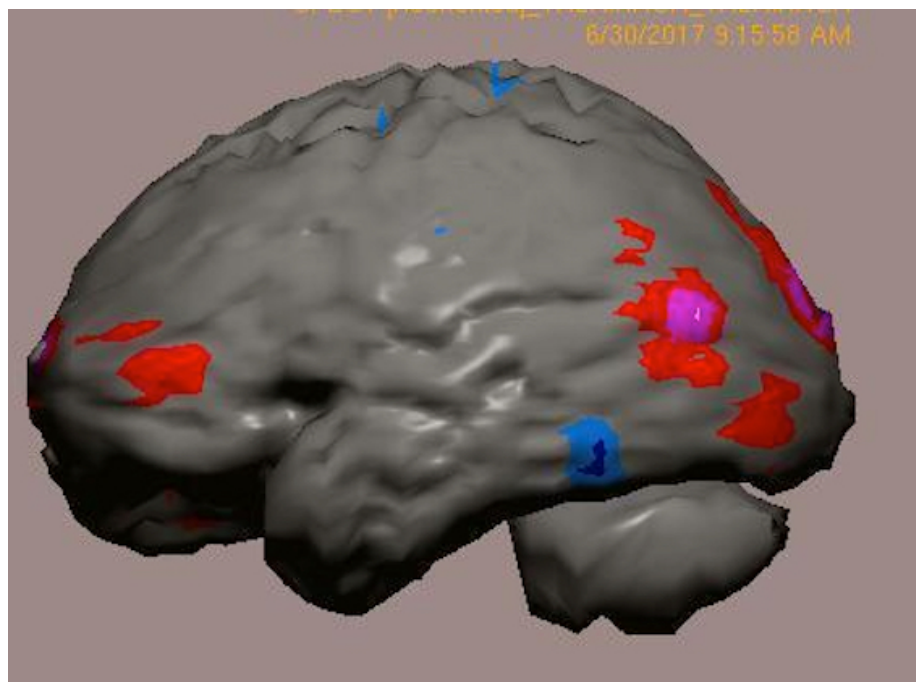
Bar-Code of
Blood Supply Perfusion
in Standard Deviations



This is the brain from the PhD researcher
This is the typical of what we would see in the UK with
available UK SPECT Software

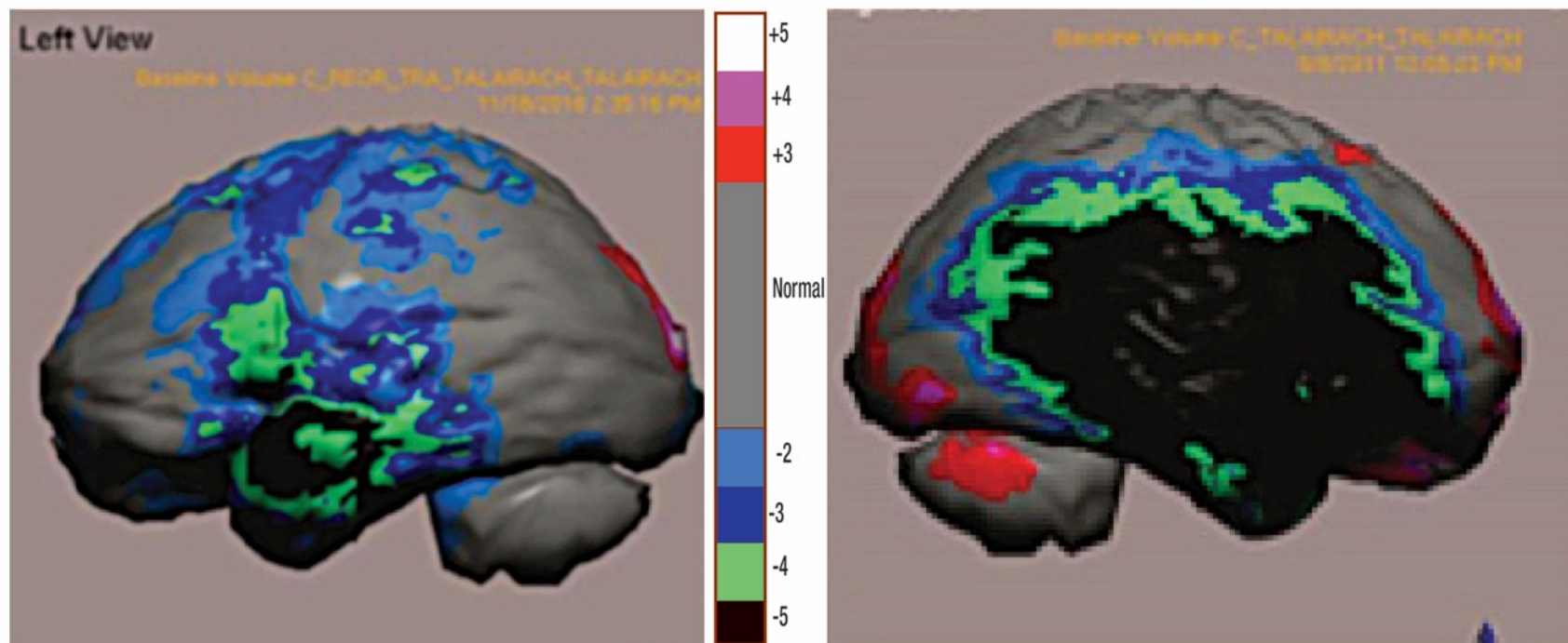


Toxic Brain SPECT Map from Ontario: Segami Oasis Software

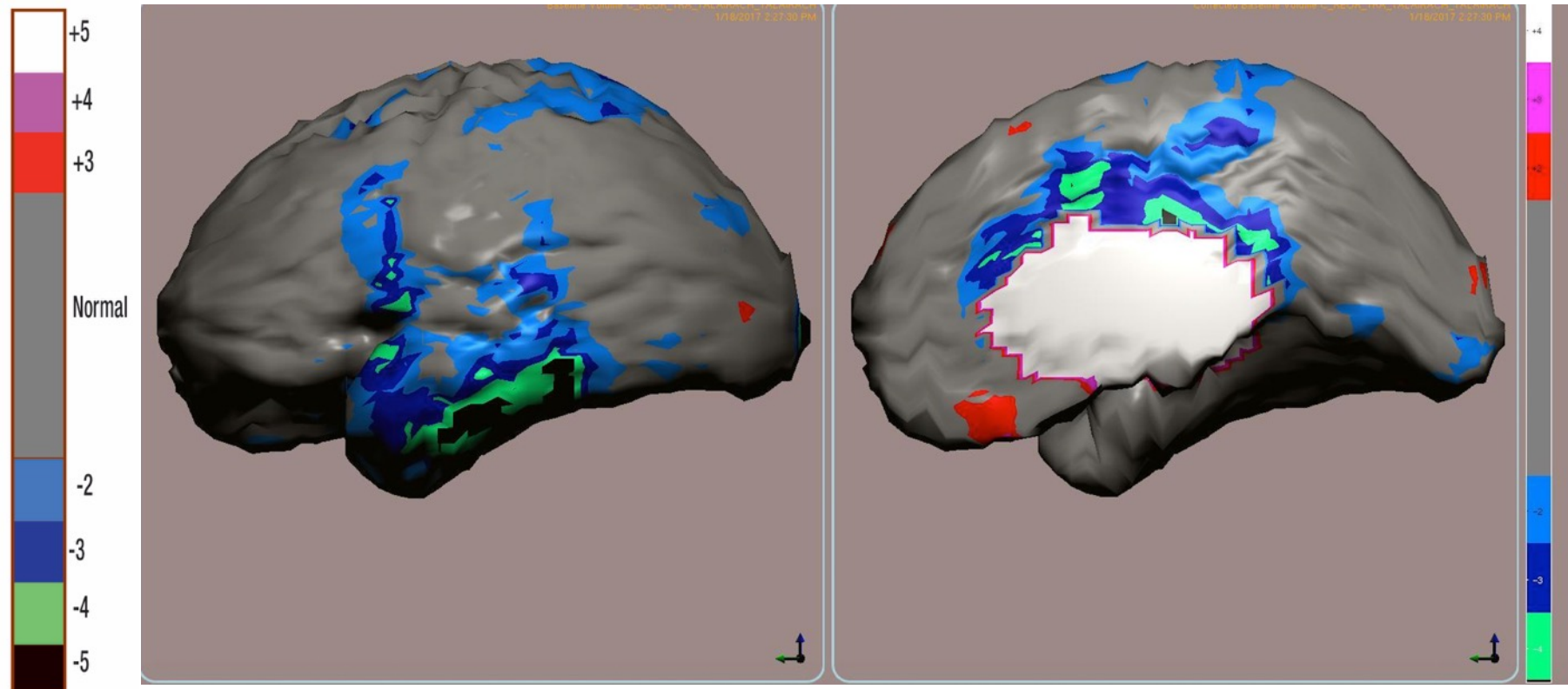


PhD working in pesticide / herbicide research
Clean Temporal Lobe & Cerebellum.
Red areas: Probably anxiety

Brain Image of a Stroke Victim

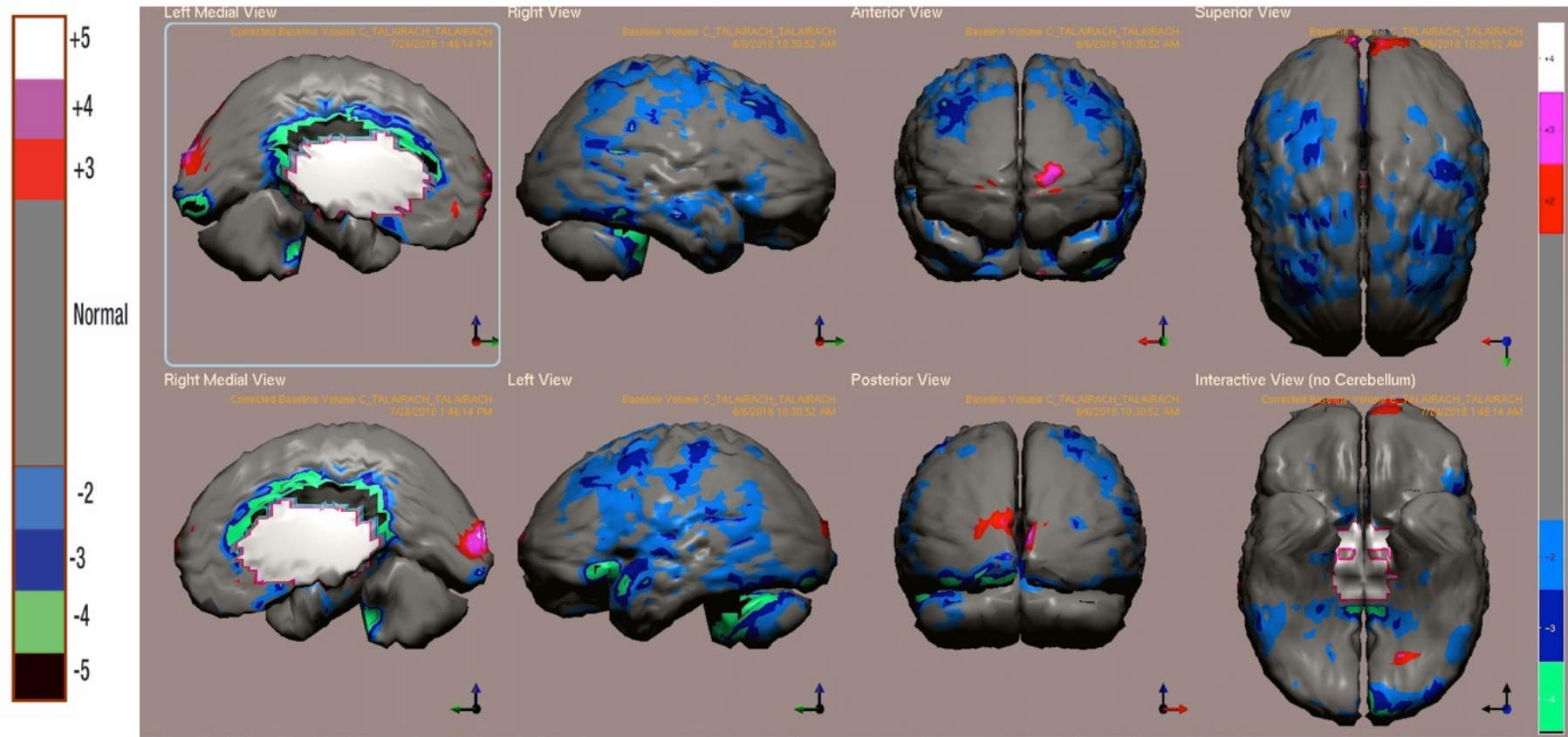


This is Merlin, emergency nurse NB/Quebec border



This brain demonstrates black areas in the anterior and middle Left temporal lobe equivalent to a stroke. This area affected her cardiac function... Merlin would have died but we put in a cardiac pacemaker which has kept her heart running.

This is an engineer poisoned by his wife with mercury.
He doesn't have M.E. He has CFS



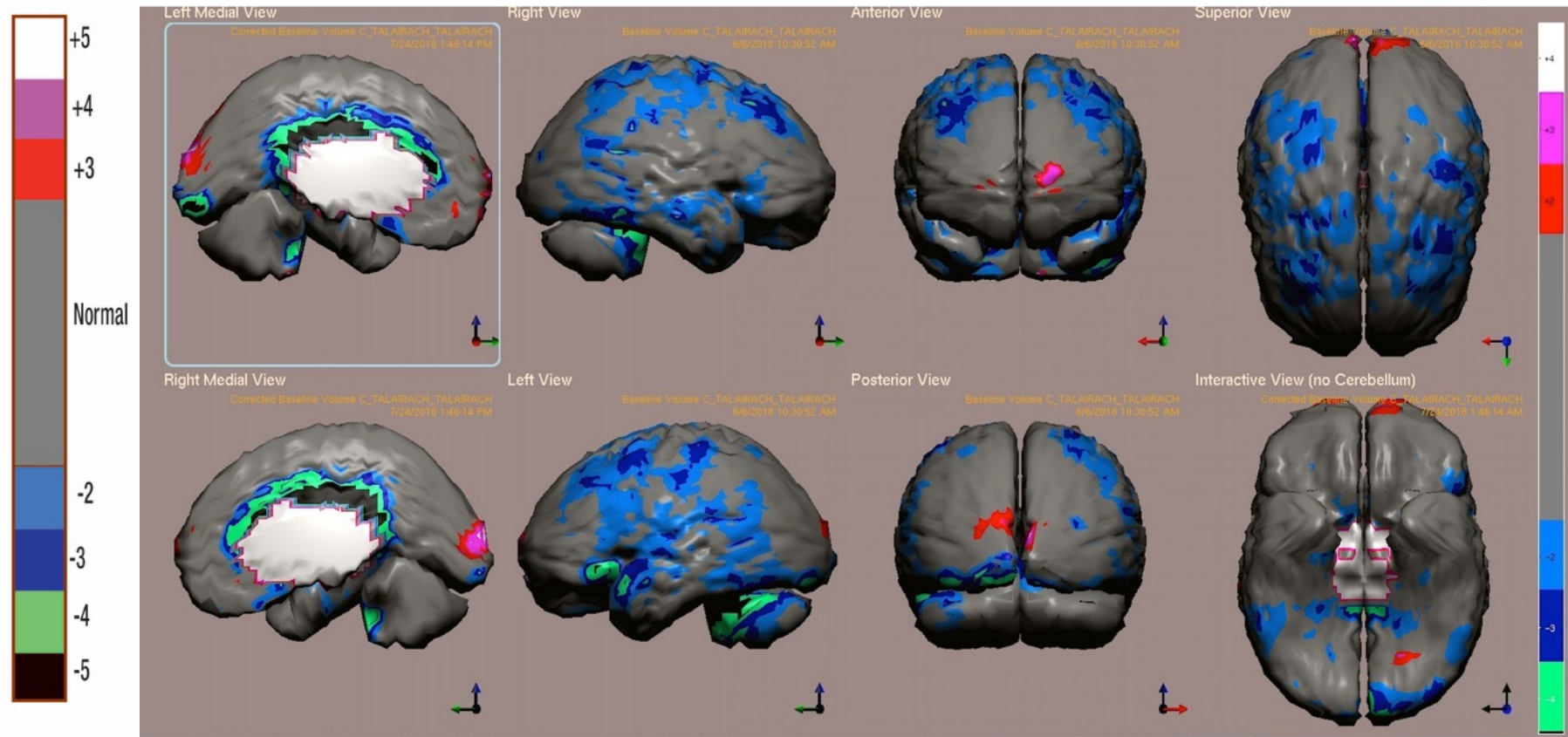
Note: (1) almost entire temporal lobe, (2) Motor cortex, (3) cerebellum,
(4) Broca's area, (5) anterior & Posterior cingulate gyrus of the limbic system

Nuclear physicians, Sonia Neubauer's Differential Diagnosis is:

**Incipient Alzheimer's
Exposure to neurotoxic substances
Cognitive impairment.**

Note: Insula & Vermix Injury

This is an engineer poisoned by his wife with mercury.
He doesn't have M.E. He has CFS



Note: (1) almost entire temporal lobe, (2) Motor cortex, (3) cerebellum,
(4) Broca's area, (5) anterior & Posterior cingulate gyrus of the limbic system

Note from Amy's mum to me last week, on May 5, 2019

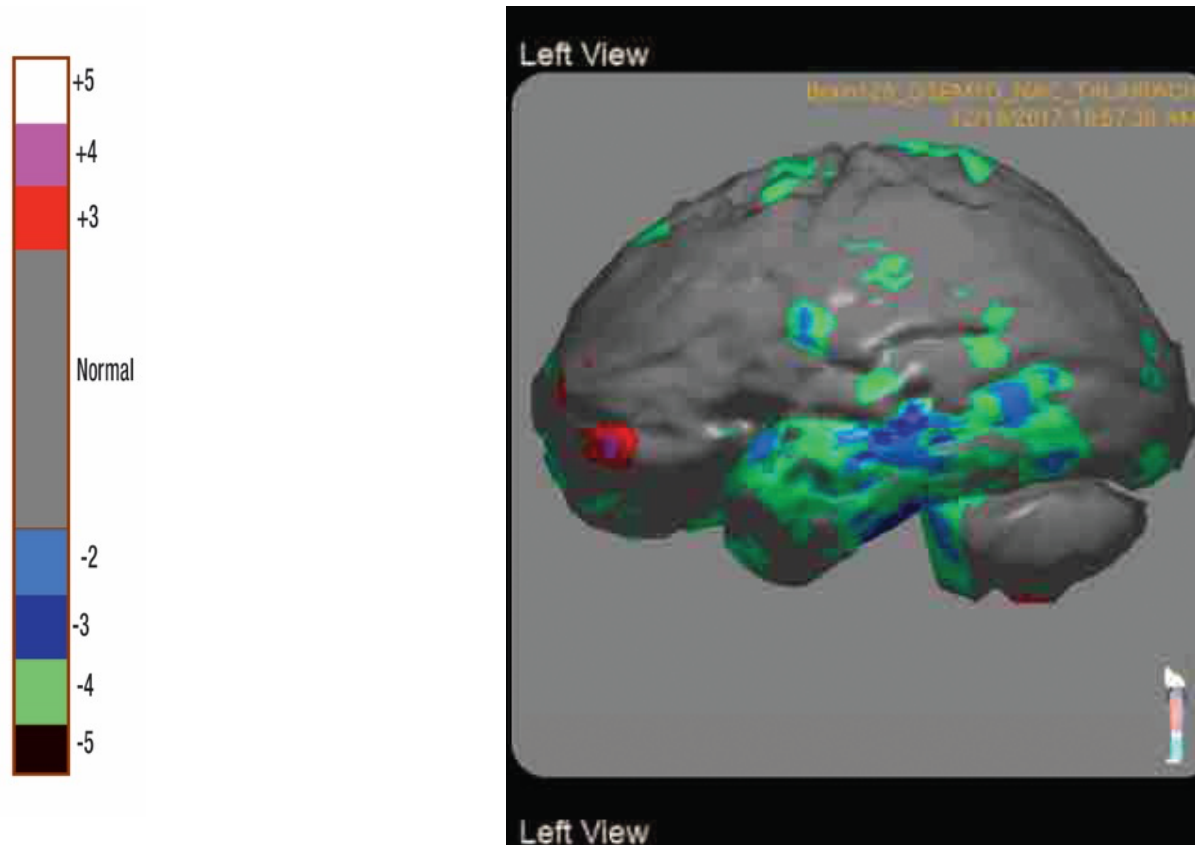
Amy is still battling on, she has been trying to walk more but hasn't managed every day, as she starts to feel faint due to her POTS, and she has to lie in her room! The GP tries to help and said: If she goes to see a cardiologist at Southampton Children's Hospital, then we could send her to London Autonomic hospital. So we took her to the Southampton hospital on Friday. It didn't go so well, she said she won't go there again!

Amy gets really down when her physical symptoms are bad! Also she has memory problems. When she looks back at things she has written it can be jumbled but she never notices this when she is writing them!

She has asked me to help her find ideas for what she can do as a career so I'm pleased she is trying to focus on the future. She has been doing the exercises you gave her mostly every day when she can.

Southampton = Section 27

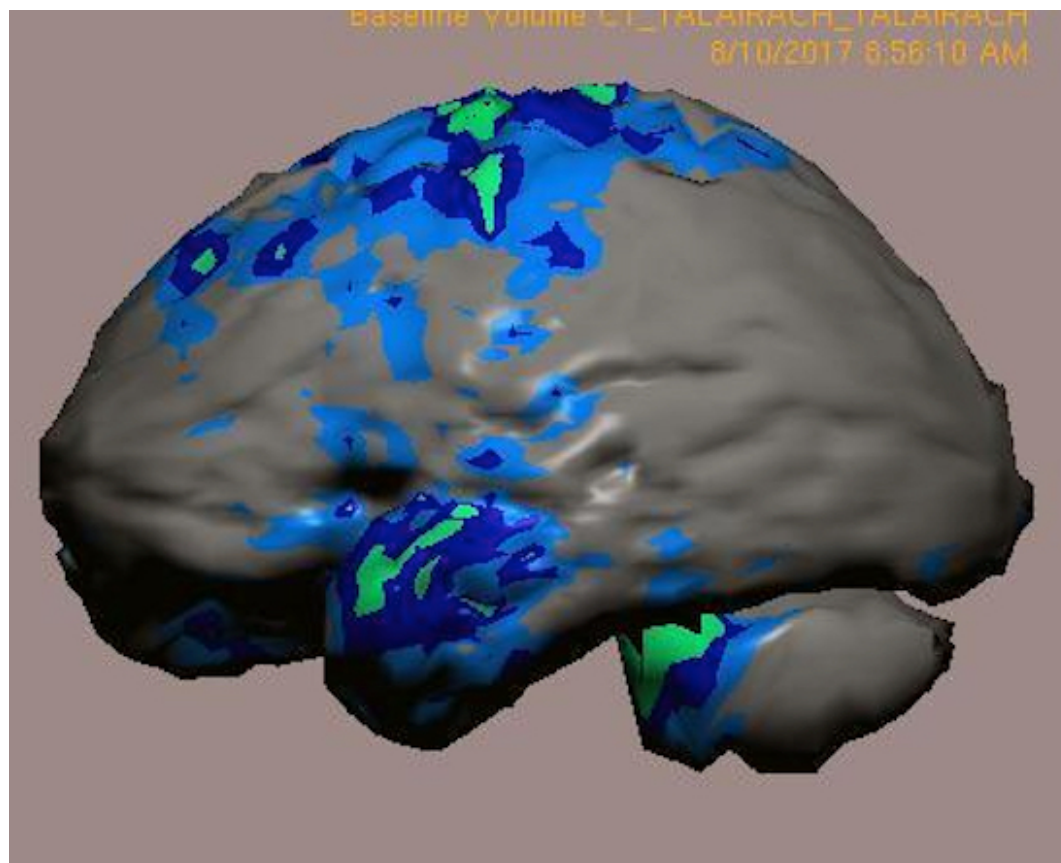
Amy's Brain SPECT Map from Plymouth: Segami Oasis Software



Left Temporal Lobe. information recall.

The Cerebella Vermis: responsible in part for POTS

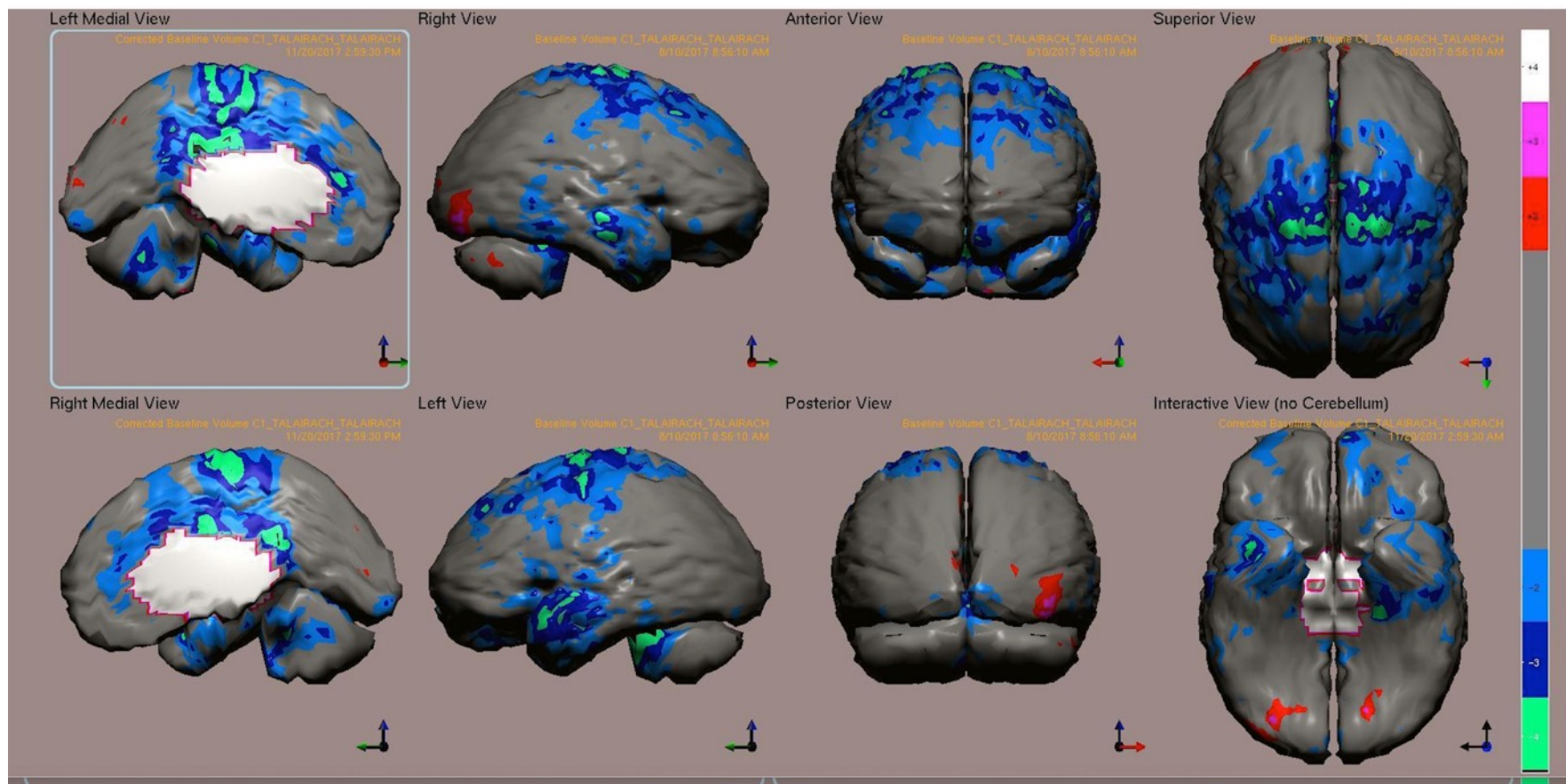
Nurse's Brain SPECT Map from Quebec: Segami Oasis Software



Left Temporal Lobe. information recall.

The Cerebella Vermis: responsible in part for POTS

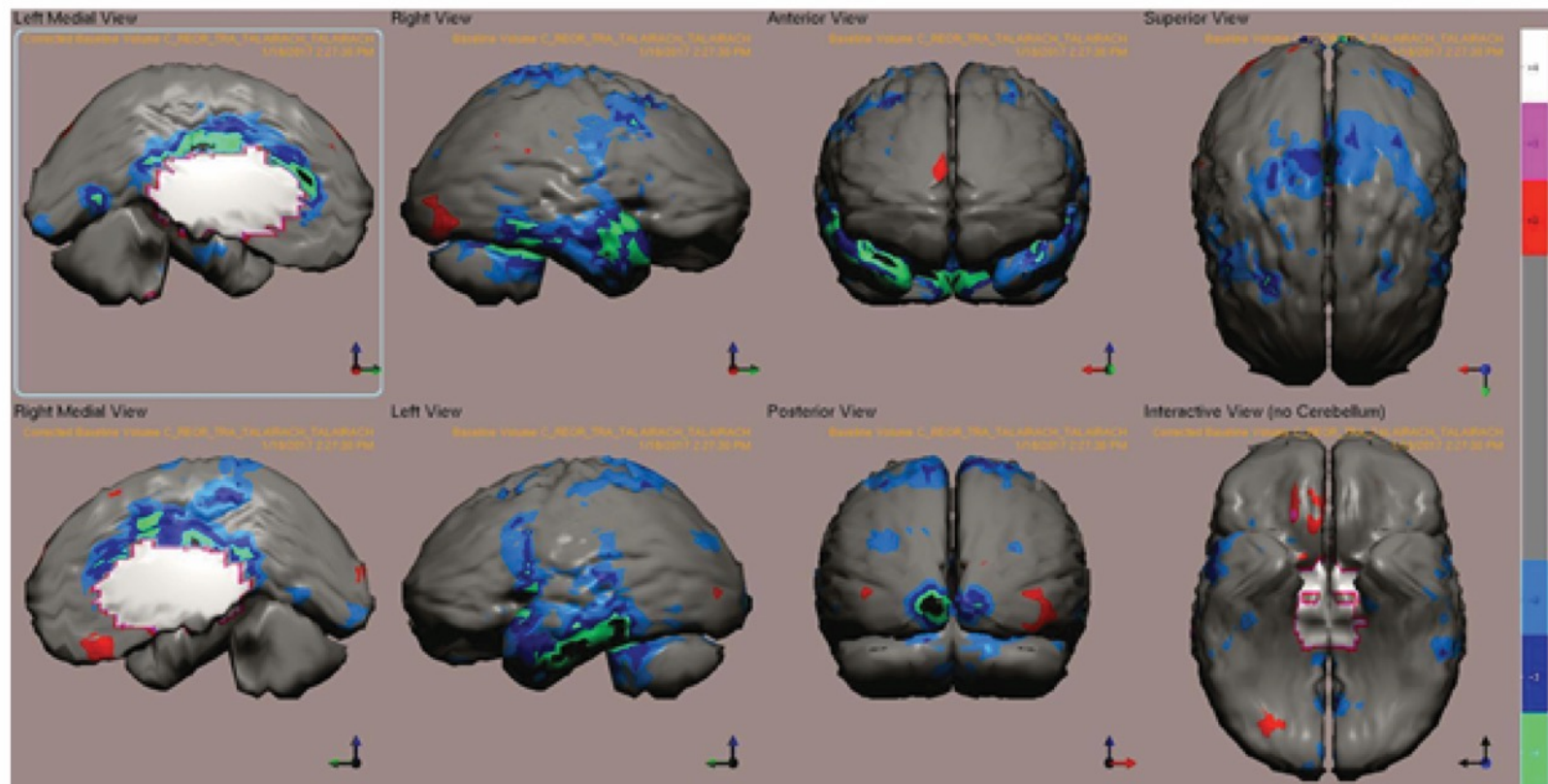
Nurse's Brain SPECT Map from Quebec: Segami Oasis Software



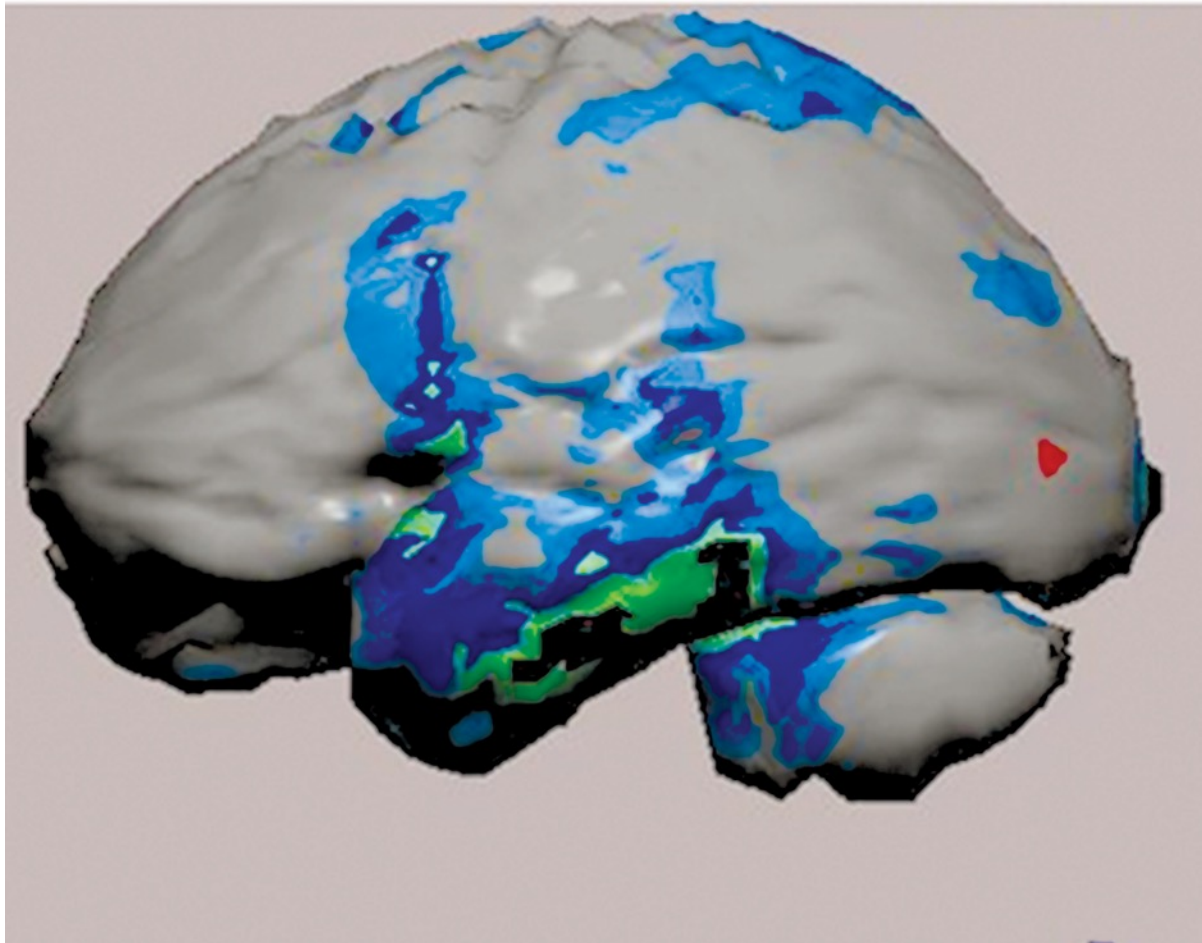
Left Temporal Lobe. information recall.

The Cerebella Vermis: responsible in part for POTS

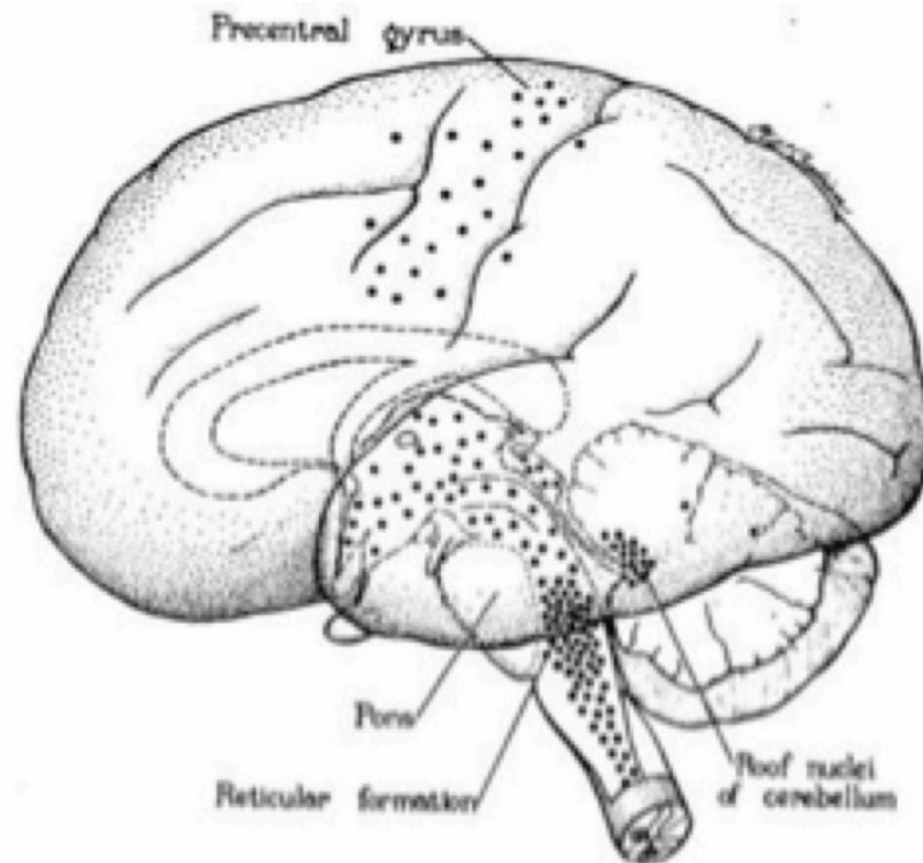
Merlin's Brain SPECT Map from NB: Segami Oasis Software



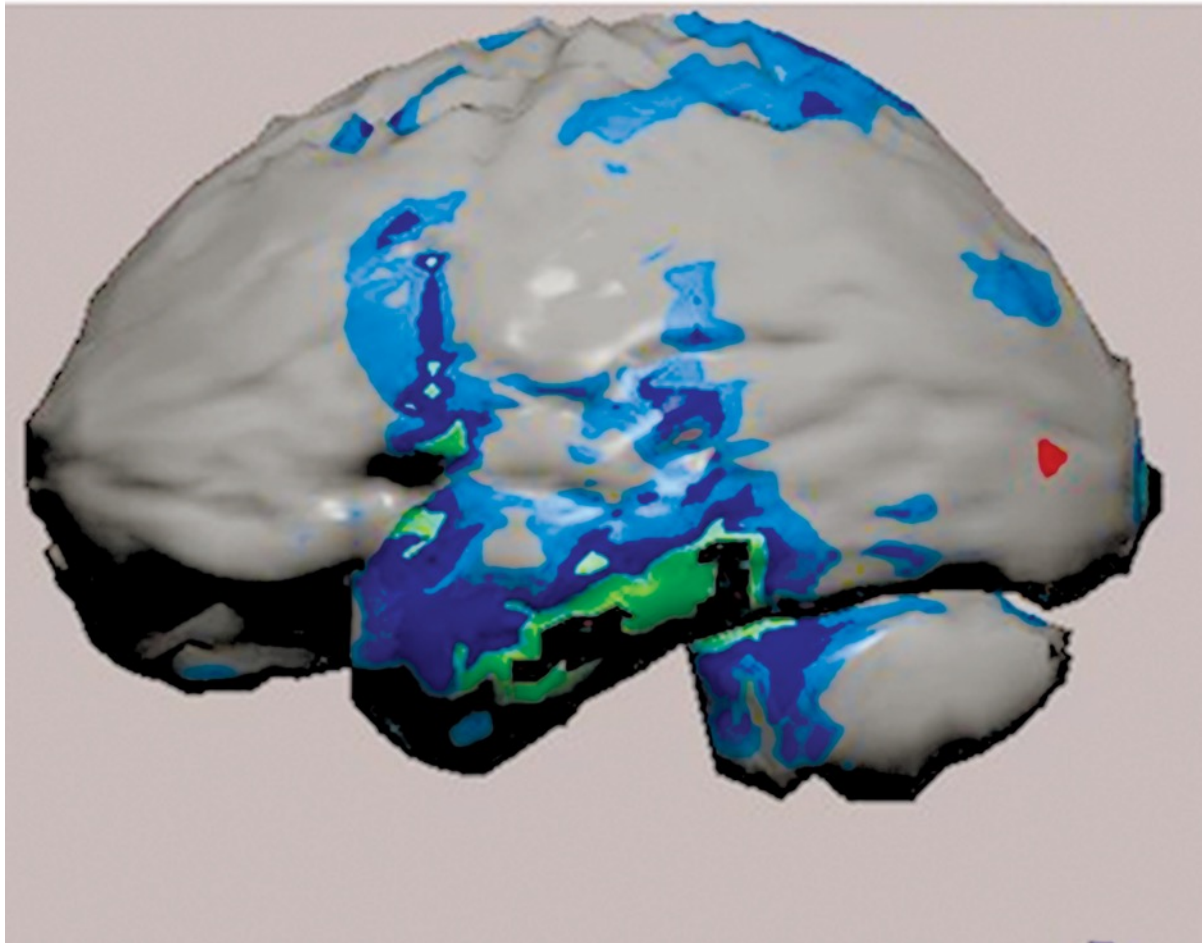
Merlin's Brain SPECT Map from NB: Segami Oasis Software



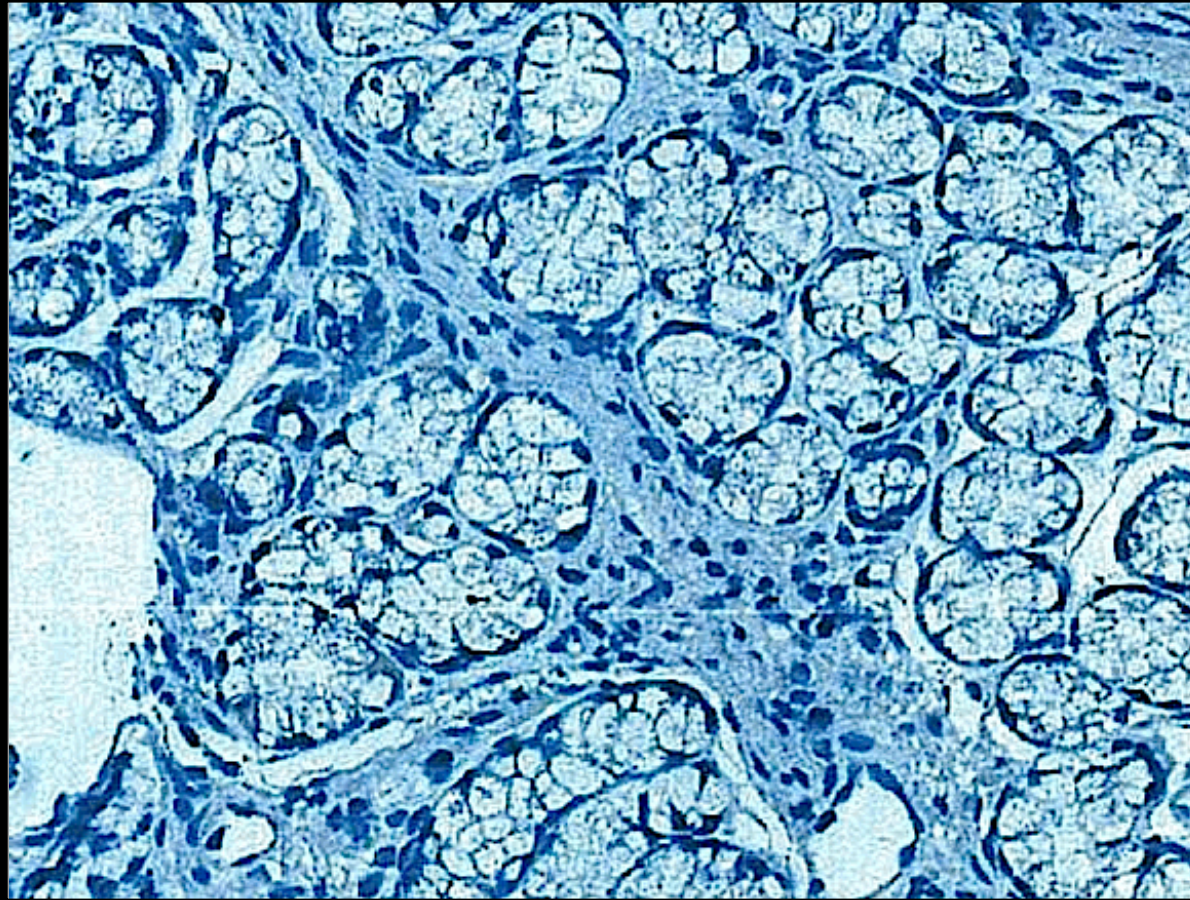
Autopsy Image of a Patient Who Died From Polio



Merlin's Brain SPECT Map from NB: Segami Oasis Software

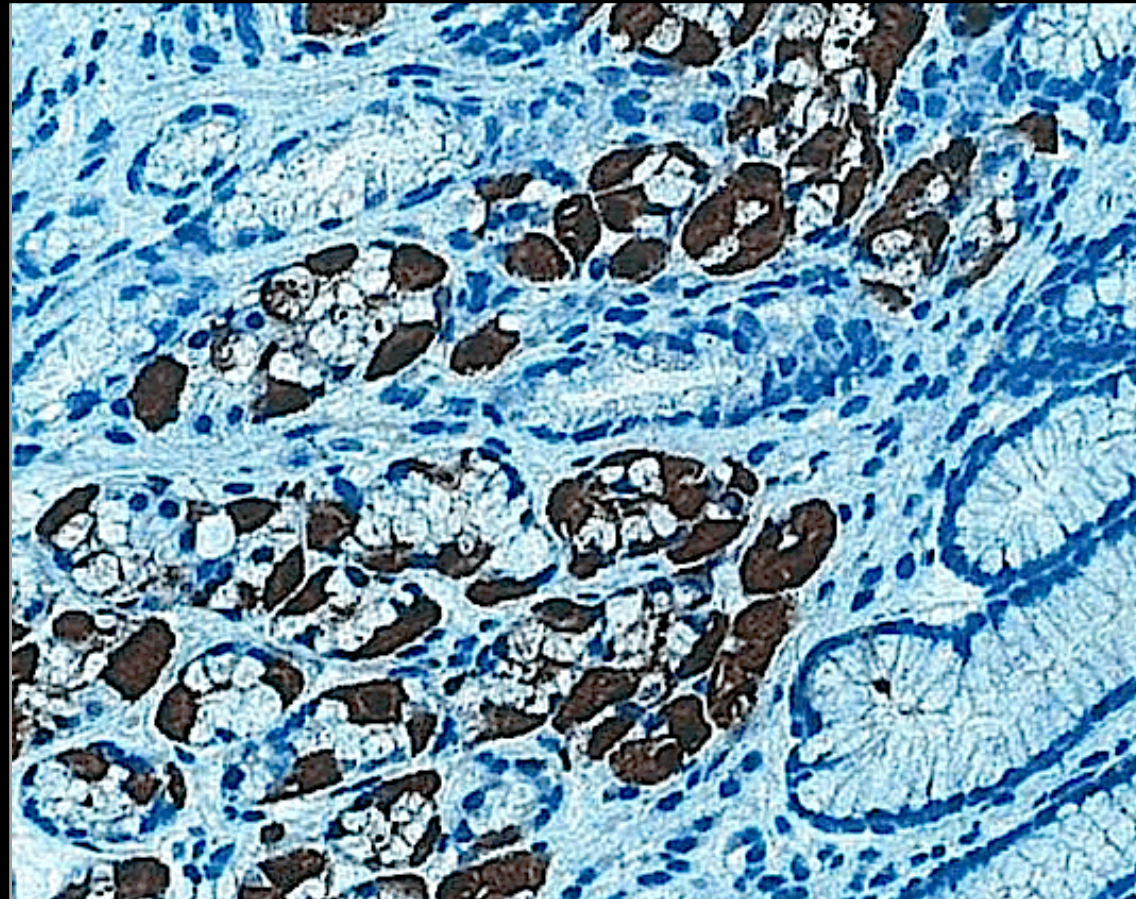


Normal Gastric Mucosa

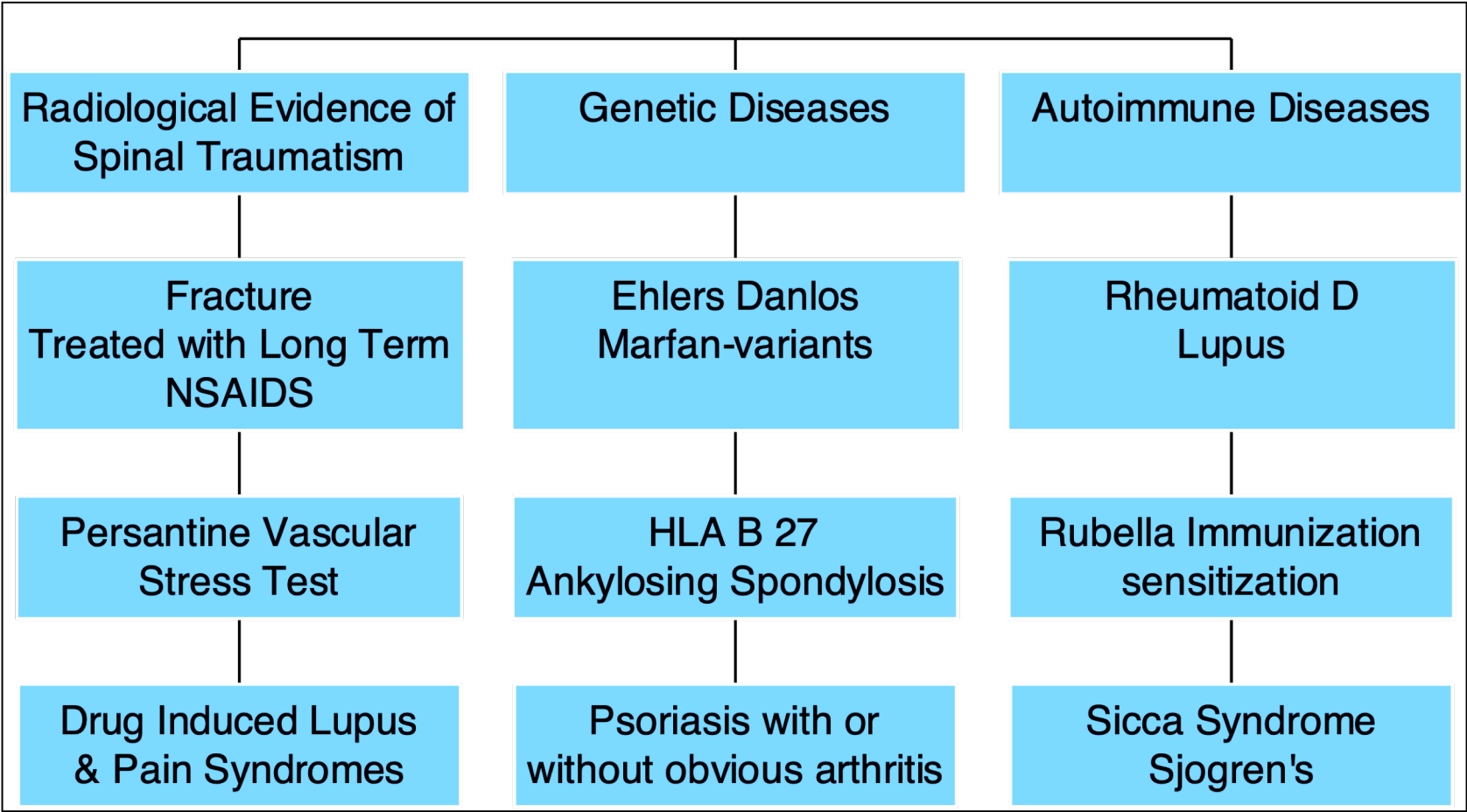


Young woman with fatigue syndrome

Enteroviral Positive Gastric Mucosa



Some Causes of Fibromyalgia



Suggested NHS GP Schedule: 20 Fifteen-minute Morning Appointments – December 2018 –

The NHS also suggests
the appointments can be shorter.
At no place does the NHS suggest
they can be longer

NHS Suggested GP Schedule

Up to 20 Fifteen-minute appointments are scheduled for the AM

Time	Appointment type	Appointment Status	Publication
08:00	Admin	Available	Not included
08:15	Admin	Available	Not included
08:30	Admin	Available	Not included
08:45	Admin	Available	Not included
09:00	Face to face consultation	Attended	Included
09:10	Face to face consultation	Attended	Included
09:20	Face to face consultation	Attended	Included
09:30	Face to face consultation	DNA	Included

The Terrible Tale of Amy Brown

A Classical Tale of Myalgic Encephalomyelitis

Matryoshka or Babushka Russian Nesting Dolls



9 Year-Old Amy fell ill in December 2014

1. Temperature: 40 C / 104 F
2. Severe sore throat
3. Rash on and in mouth
4. Rash on fingers
5. Worst Headache in her life
6. Semi-comatose
7. Failure to recover after two weeks
8. Two hospitalizations
9. Syncope, diagnosed as seizures

Seen by 47 Physicians and two hospitalizations over two years

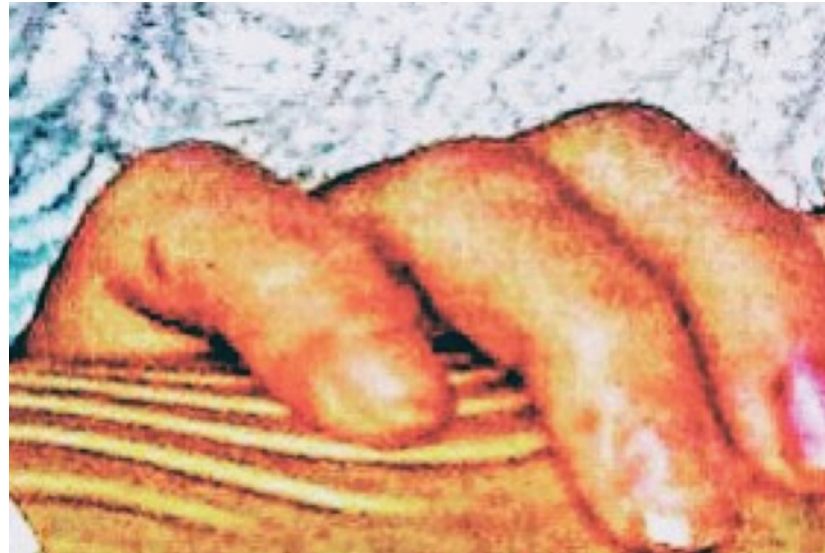Incorrectly diagnosed as:

1. Herpes simplex lesions on her mouth
2. Internal mucosal lesions caused by Amy biting herself
3. Epileptic Seizures
4. Treated for Epilepsy, despite normal EEG
5. Anxiety Neurosis
6. Normal cardio-vascular system heart
7. Her hand-lesions diagnosed as hives
8. Chronic Fatigue Syndrome (CFS)

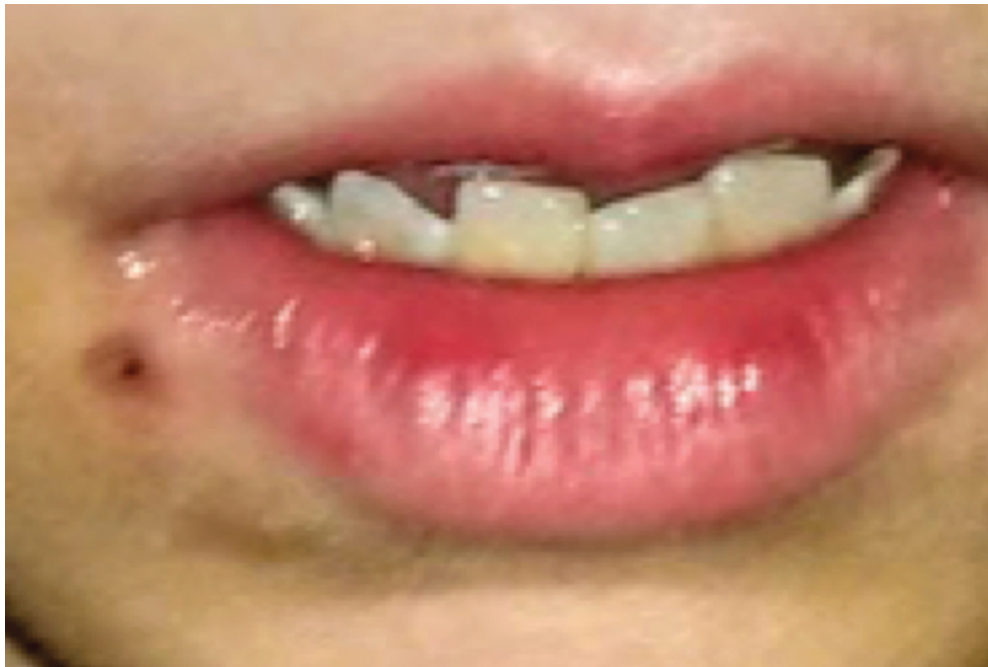Revenge of the treating physician?

1. Parents considered critical of doctors' diagnoses
2. So doctors sectioned Amy under Section 47
3. Amy sent to a school for psychiatric children
 - Psychotic young boy beats up the teacher
4. Parents remove Amy from the school
5. Family hides out Amy from the medical system

What was the real diagnosis?



Amy's swollen fingers with red blisters



Amy's swollen lips with red blisters

The Second Matryoshka Doll



What Really Happened:

1. Amy falls ill: classical Hand-Foot-and-Mouth disease
2. Typical hand and mouth lesions due to EV71
3. During EV71 HFM epidemic in the UK
4. Develops an entero-viral encephalopathy
5. Viral meningeal severe head pain
6. Temperature 104 F / 40 C, semi-comatose
7. Normal standing blood pressure 118/79
8. Drops to 61/30 in 8 minutes standing
9. Collapses on bed in typical POTS reaction

Brain Injury secondary due to Encephalopathy

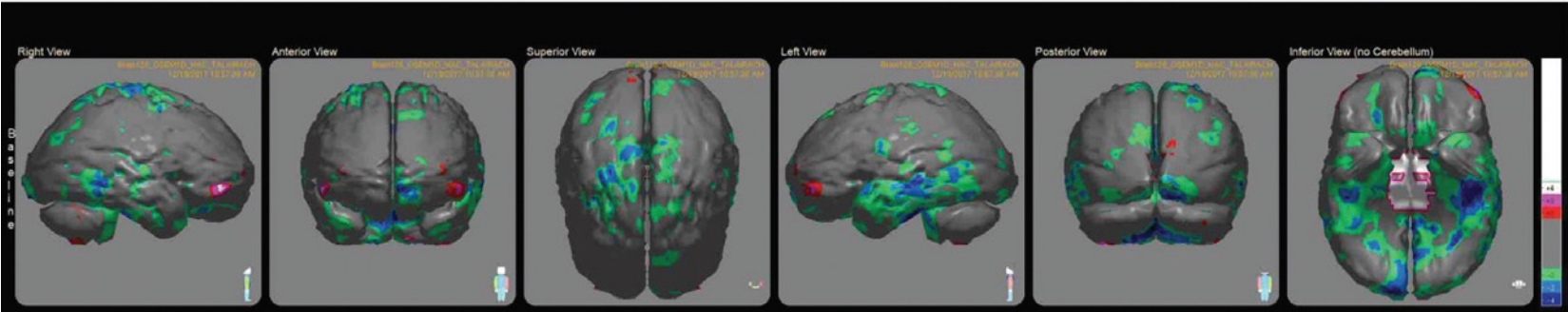
1. Develops POTS due to brain injury causing syncope
2. Major cognitive weakness and difficulties reading
3. Visual changes
4. Significant muscle weakness and pain causing difficulty walking
5. Gastric difficulties
6. Amy remains chronically disabled, with classical M.E.



Classical circulatory dysfunction in M.E. patients

[illegible]

The Cerebella Vermis: responsible in part for POTS



The Terrible Tale of Christopher Robert



Totally disabled immediately following
Recombinant Hep B Immunization
– A Classical Tale of Chronic Fatigue Syndrome –

Within hours of receiving RHB

- Immediately hospitalized due to seizures, transferred to Childrens' Hospital
- Christopher Robert eventually seen by **47 Canadian Physicians**,
- Hospitalised in 3 Canadian Hospitals, two University Medical Centres.
- He remained ill from 11 to 23 years after receiving RHB Immunization
- Previously a top student, now repeatedly had poor grades
- He was diagnosed with conversion disorder (hysteria)
- His mother diagnosed with **Munchausen Syndrome By Proxy**.

The Next Ten Years:

1. Developed severe, repeat night-time seizures
2. From age 12 until 23, night-time seizures persisted
3. Never had a full night's sleep for 10 years
4. Parents persistently explained night-time seizures to 47 doctors
5. Parents never believed
6. Doctors repeatedly performed day-time EEG's and found nothing
7. Doctors then diagnosed psychotic attention seeking
8. Lost consciousness in swimming pool during seizure and drowned
9. Rescued by life-guard
10. At 23, Christopher Robert unable to work. Education destroyed

I first saw Christopher at age 23,
chronically ill since 11 years of age
and I found the following:

First Impression

1. Psychologically normal young man
2. I diagnosed Ehlers Danlos Hyper-flexible Syndrome (EDS)
3. Tonsils totally occluded pharynx
4. Reputedly none of the 47 doctors asked him to open his mouth
5. I suspected tonsils blocked respiration causing seizures
6. Tonsils removed, seizures continued
7. Performed night-time EEG, classical frontal seizures occurred
8. With seizures, cardiac arrest occurred
9. Moved to Cardiac Institute

1. Severe frontal night-time seizures documented
2. Cardiac arrest with seizures documented
3. Severe sleep dysfunction and falls due to seizures
4. Night-time blood-sugar, at 2.8, or lower
5. Left carotid artery blood Flow at 60%
6. Pituitary anomaly & abnormal hypertrophic thyroid
7. SPECT: severely reduced circulating brain blood volume.
8. C Reactive Protein 30.6 mg/L (normal is less than 8)
9. 24 hr. Holter Monitor Demonstrated Heart Block

U.S.A. National Vaccine Injury Compensation Program (VAERS)

VAERS has paid families who suffered death or disability following RHb immunization,
over 1 Billion Dollars

How is a physician supposed to investigate an M.E. patient in 15 minutes or a specialist in 50 minutes?

They can't!