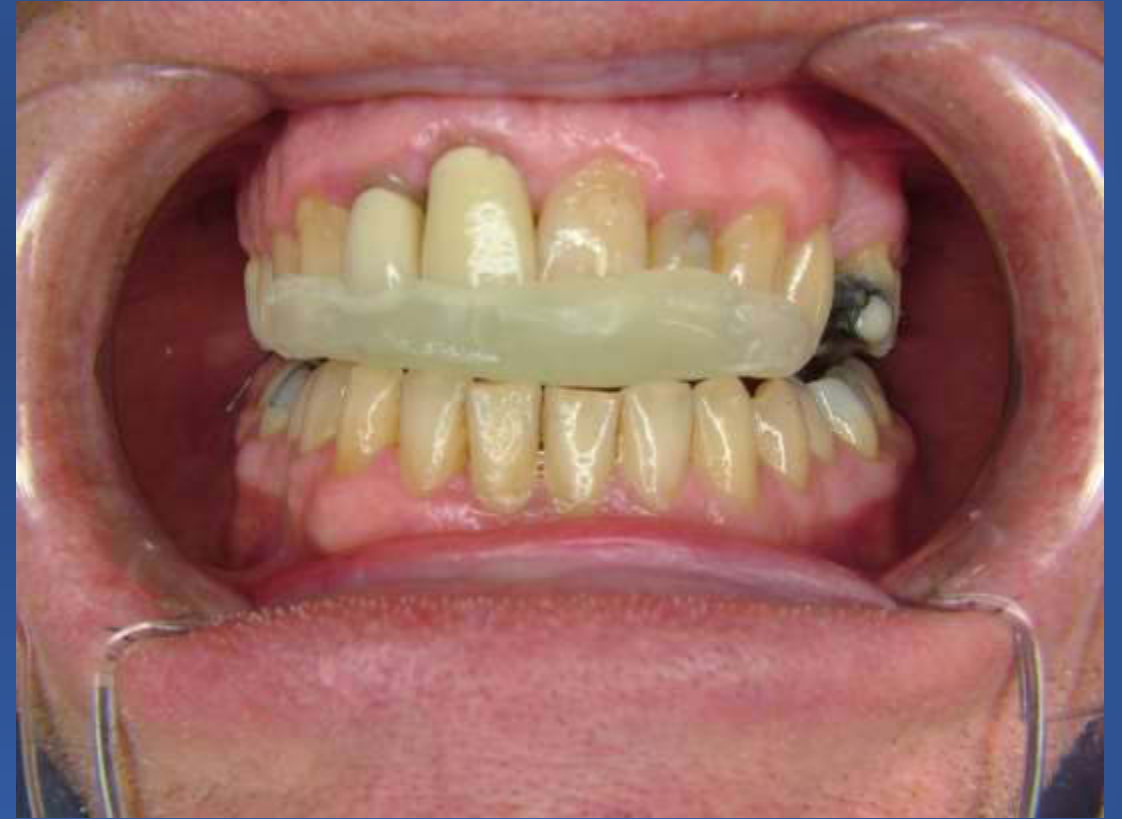
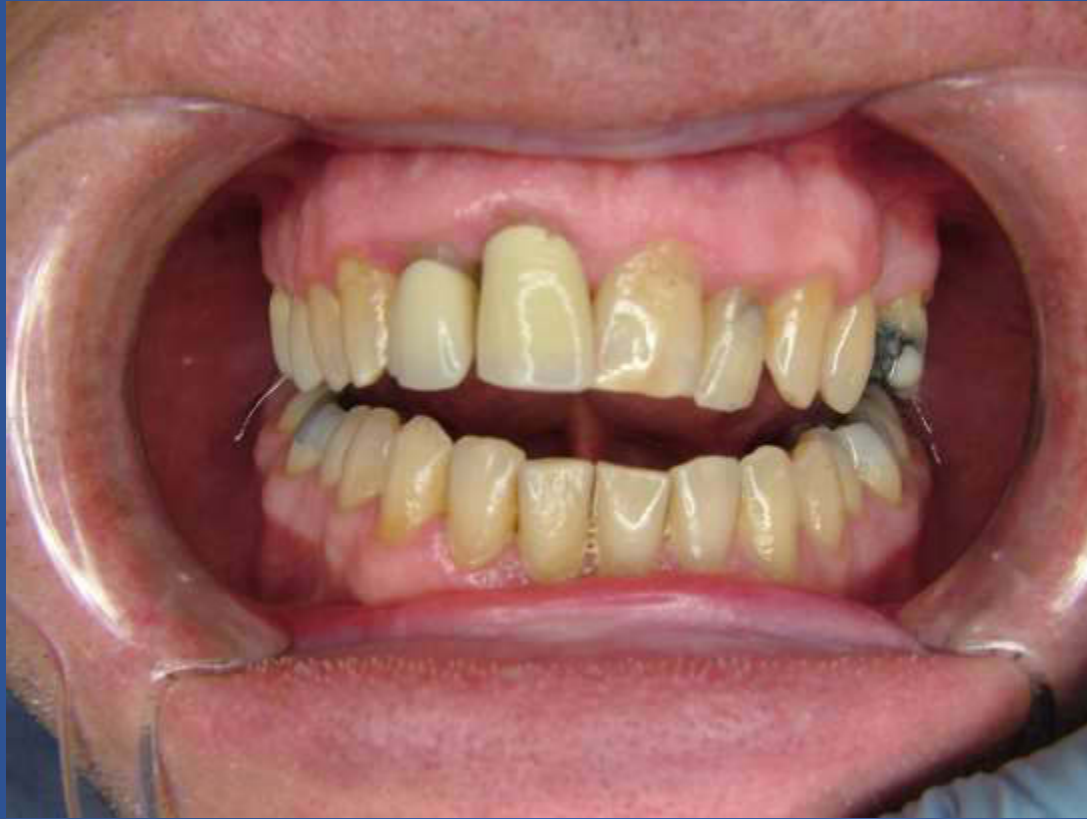
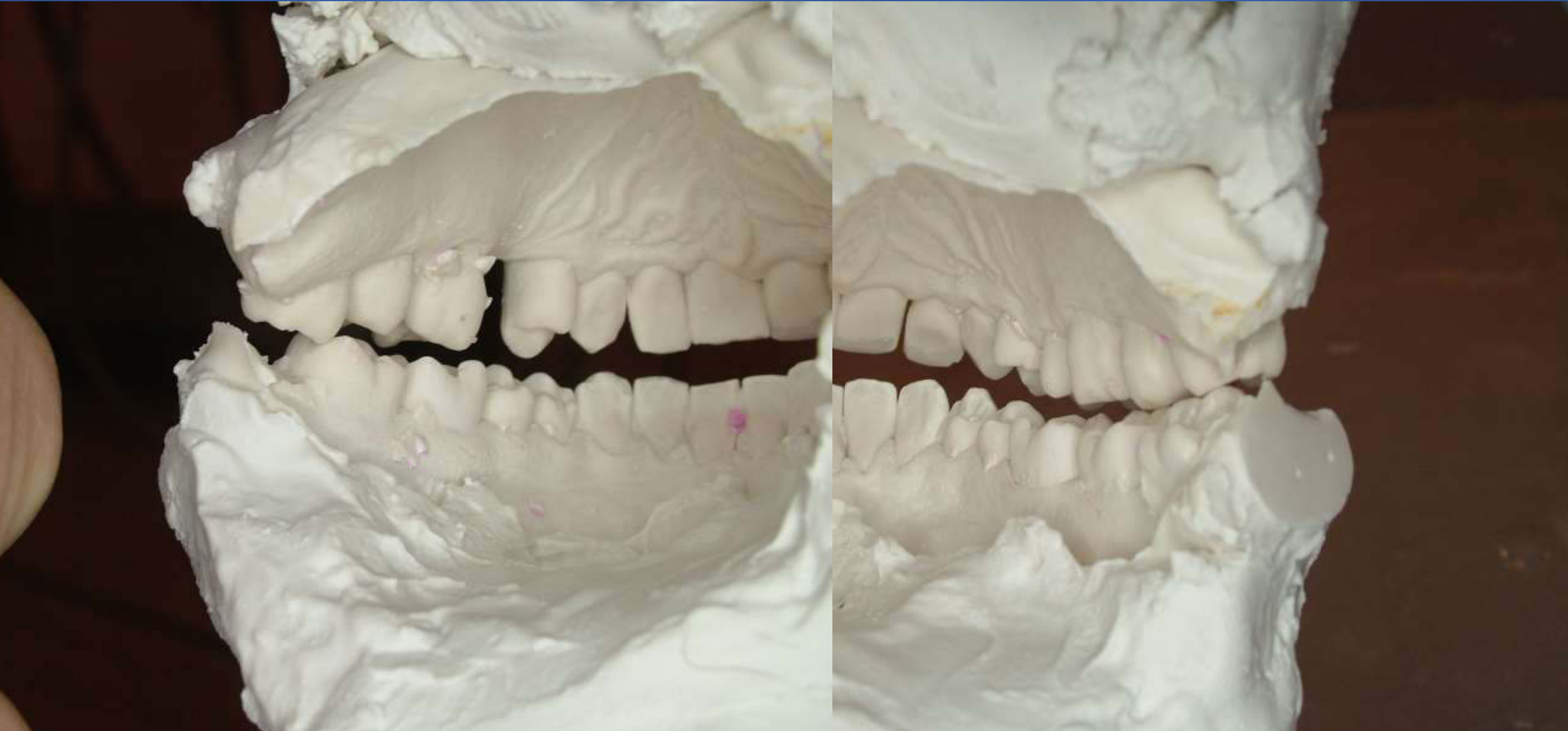Roy, Anterior Deprogrammer to pacify muscles



ROY, CRO position



ROY TMA

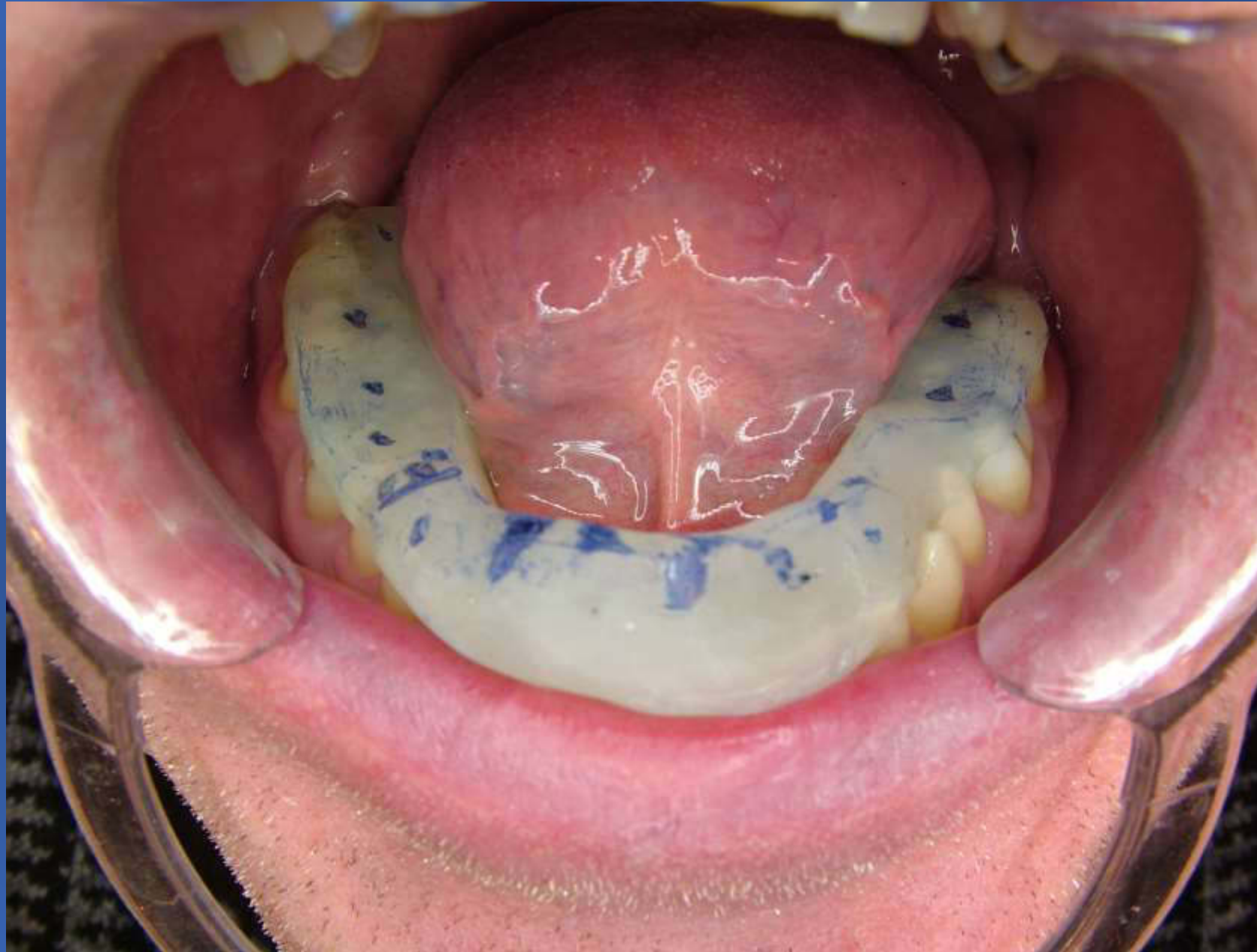
.1st examination

Severe paroxysms of
pain when right
Temporalis touched

.TMA fitted 12/2019


. WAS Taking maximum
Tegretol

. Now pain free and
taking no medication



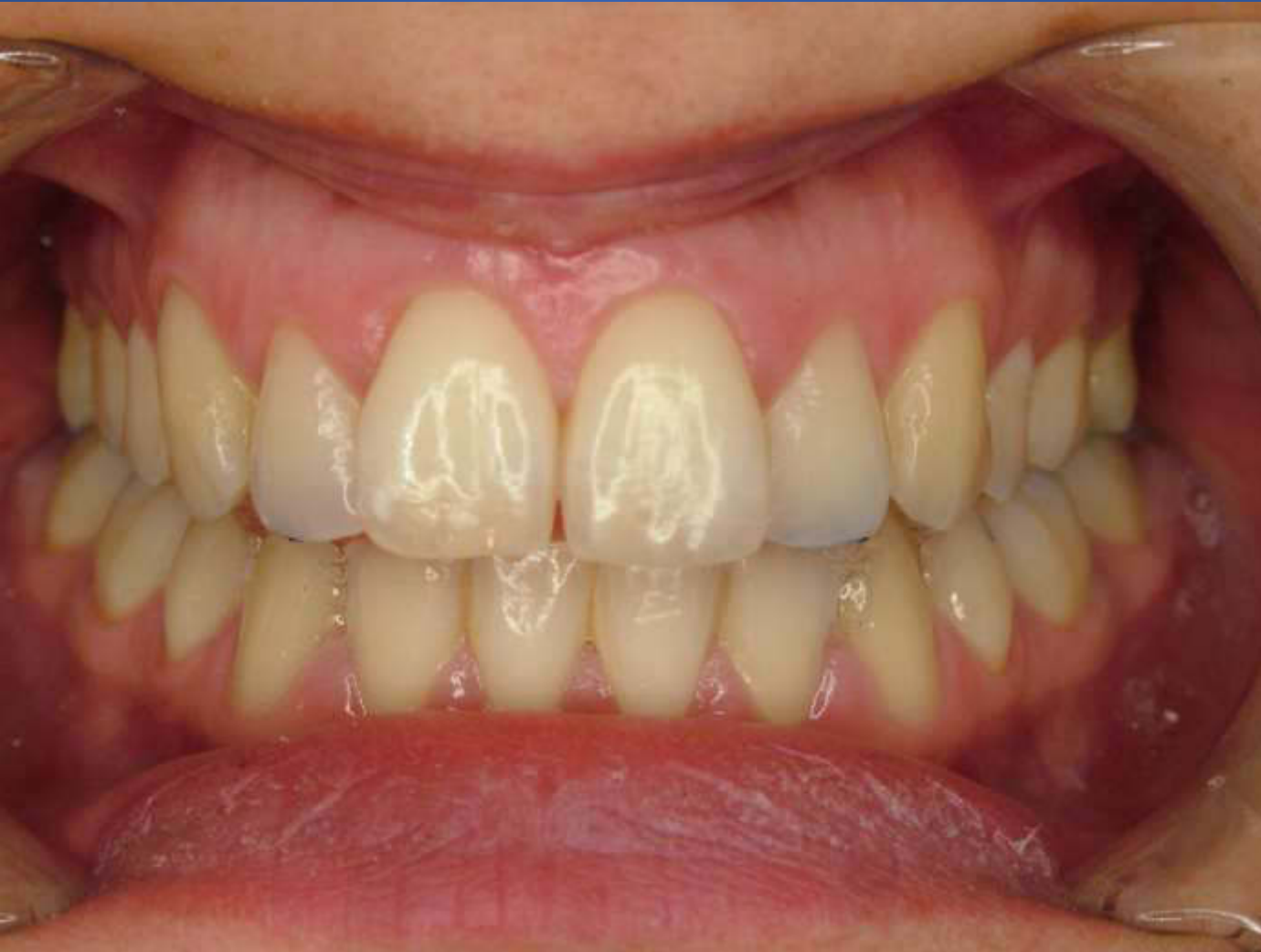

ROY



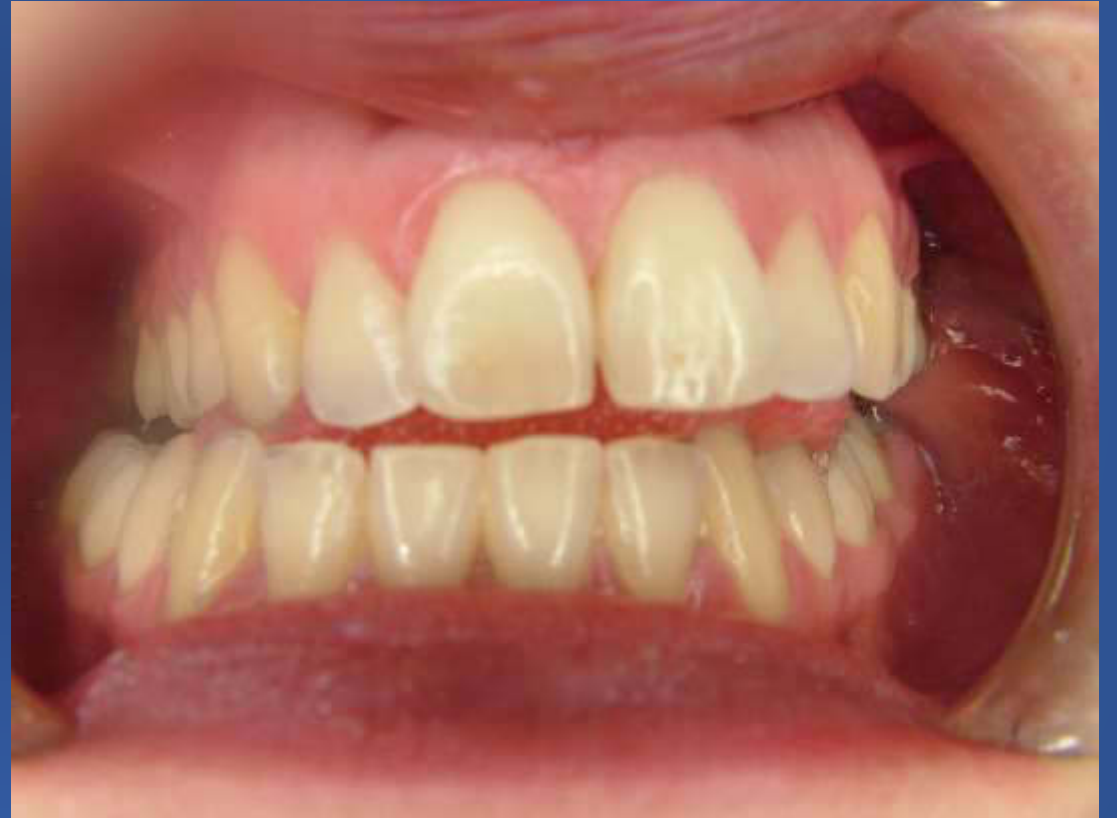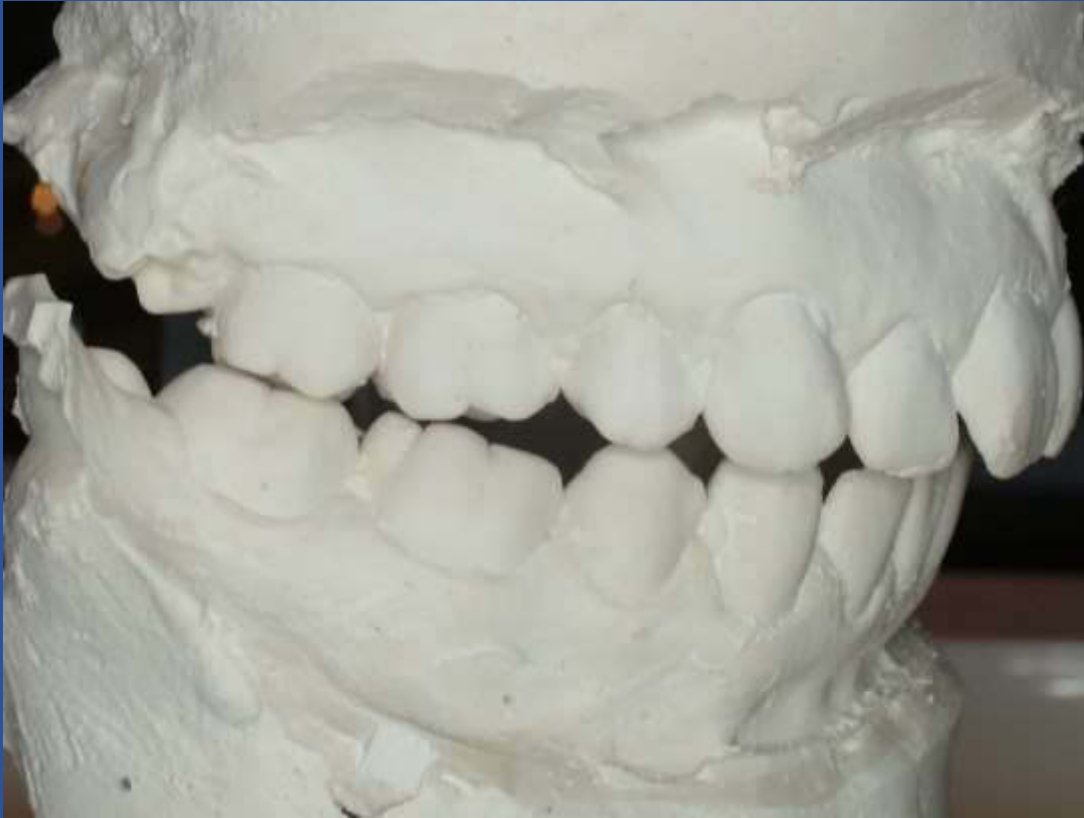3 monthly recall tooth and TMA
equilibration.
“No pain, occasional “tingle” when
adjustment due. No Medication”

Emma-Jayne Post orthodontic dysfunction

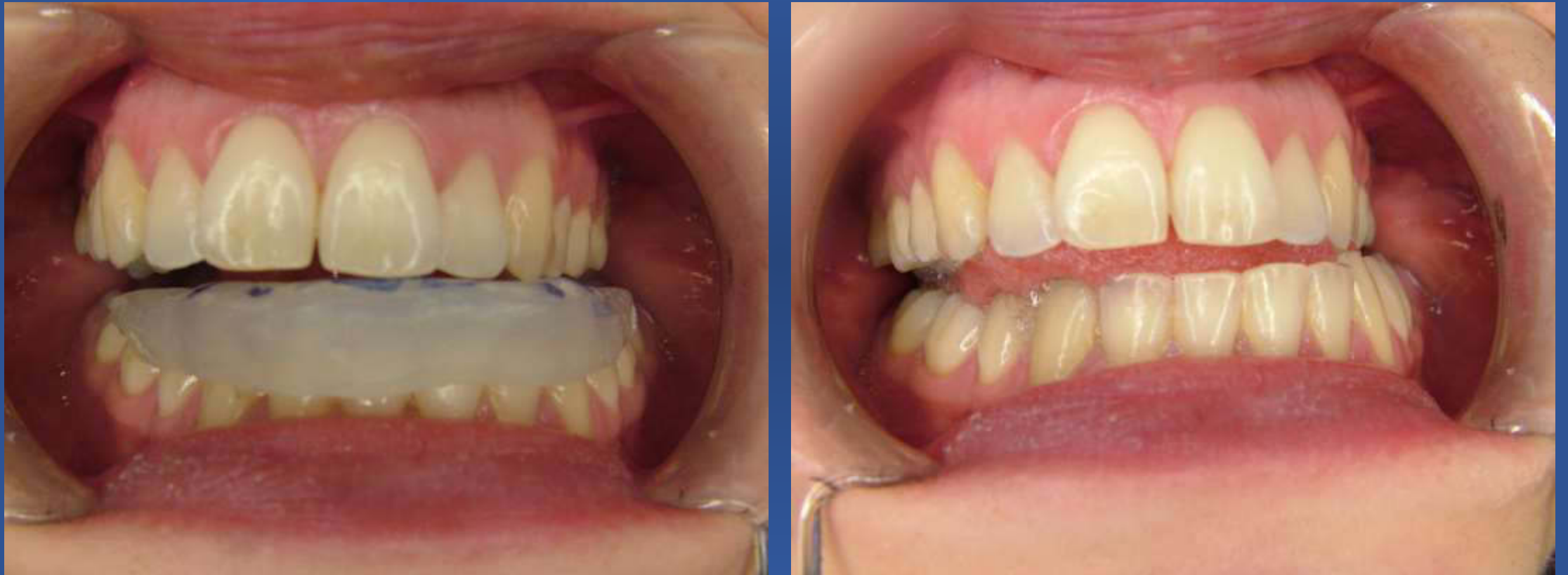

- Consulted I.S. for AO opinion 2018
- Long history of Headaches since teens
- Bicuspids extractions and fixed appliances in teens
- Limited ROM 36mm
- All muscles TTP
- Tinnitus
- Low energy

LATERAL EXCURSION, no Anterior Guidance protection. Constant parafunction stimulus and poor mechanics

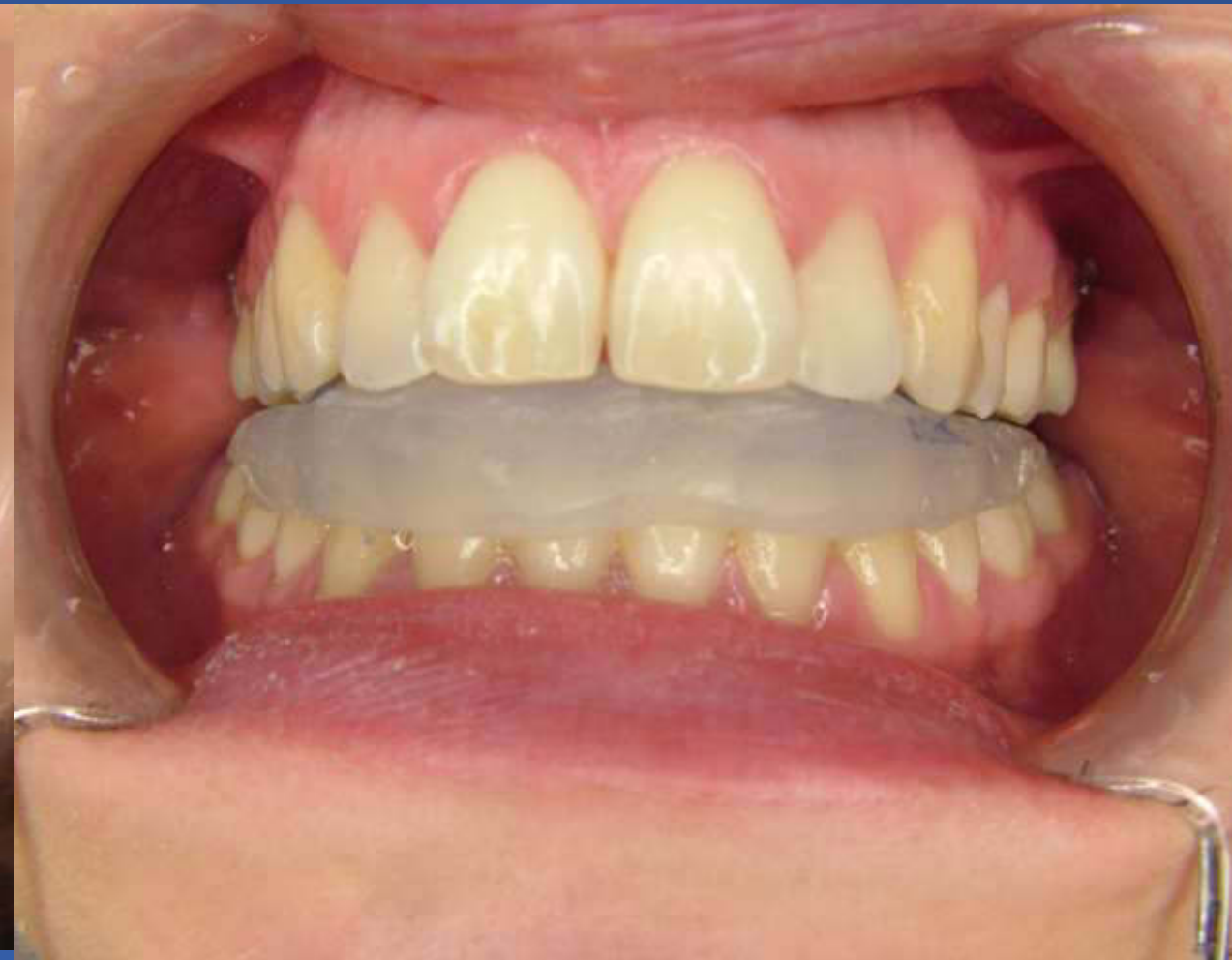
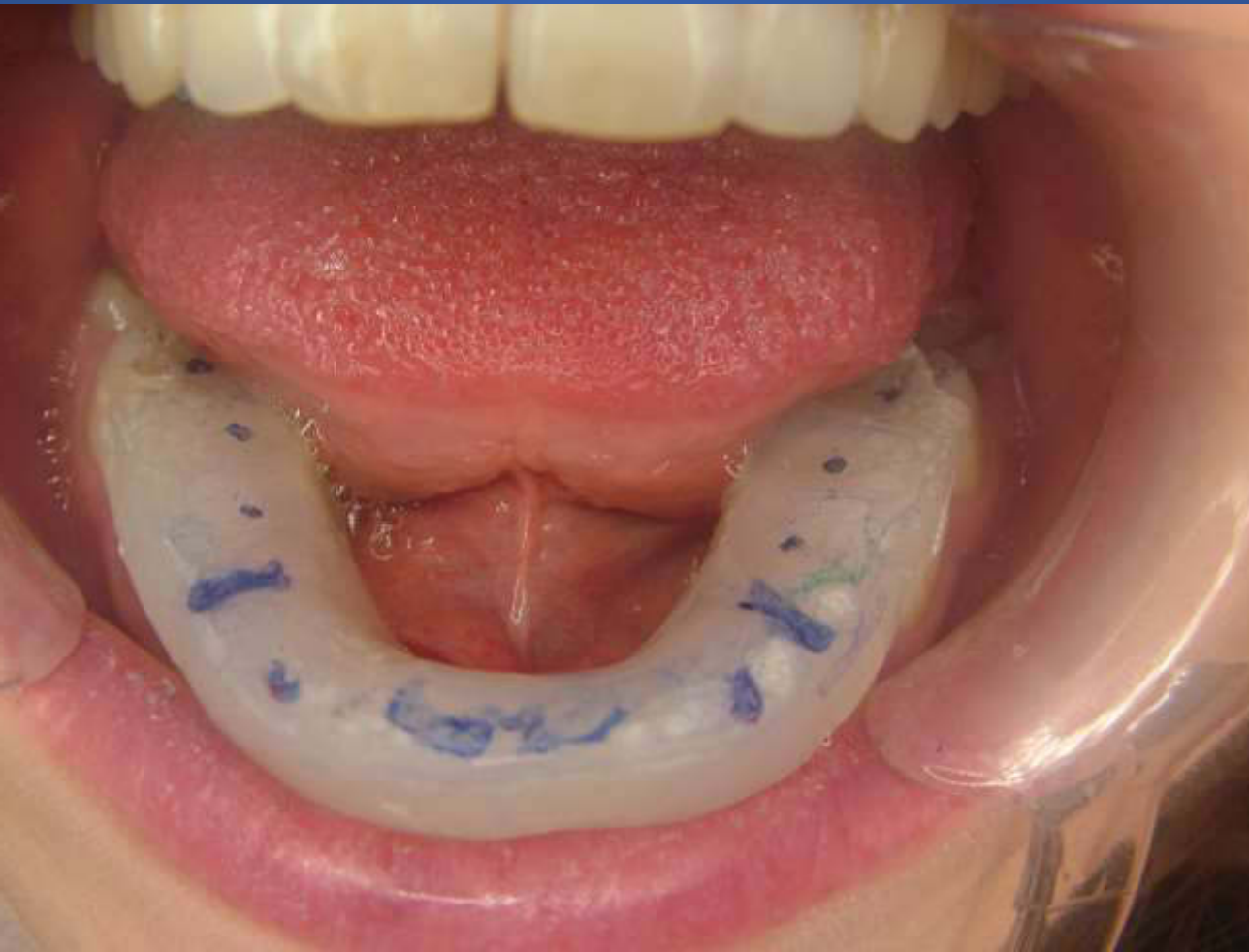
E-J with TMA, restores Anterior guidance improves function

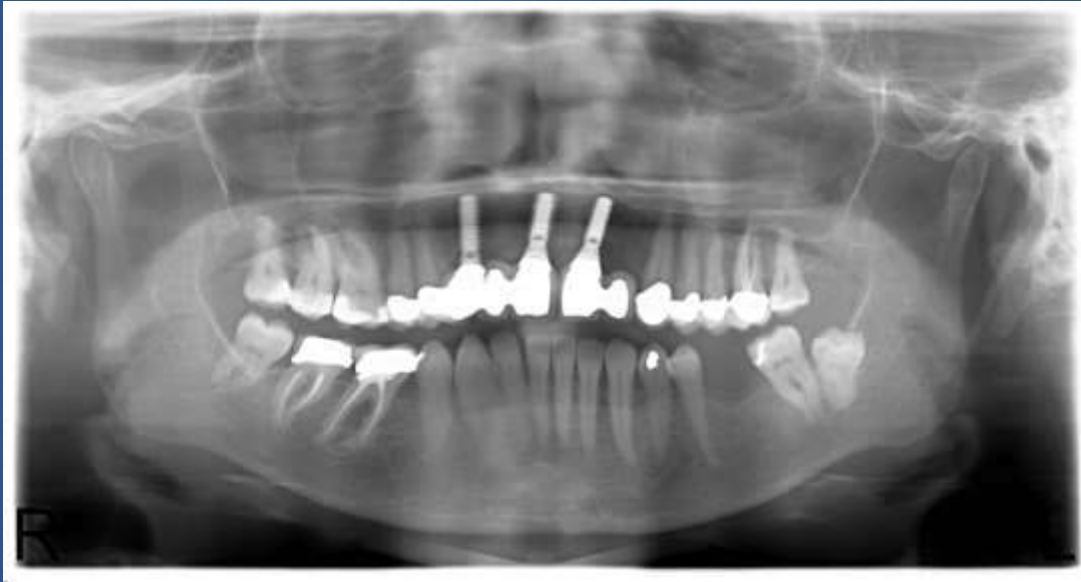

Energy increased, headaches decreased, no migraines

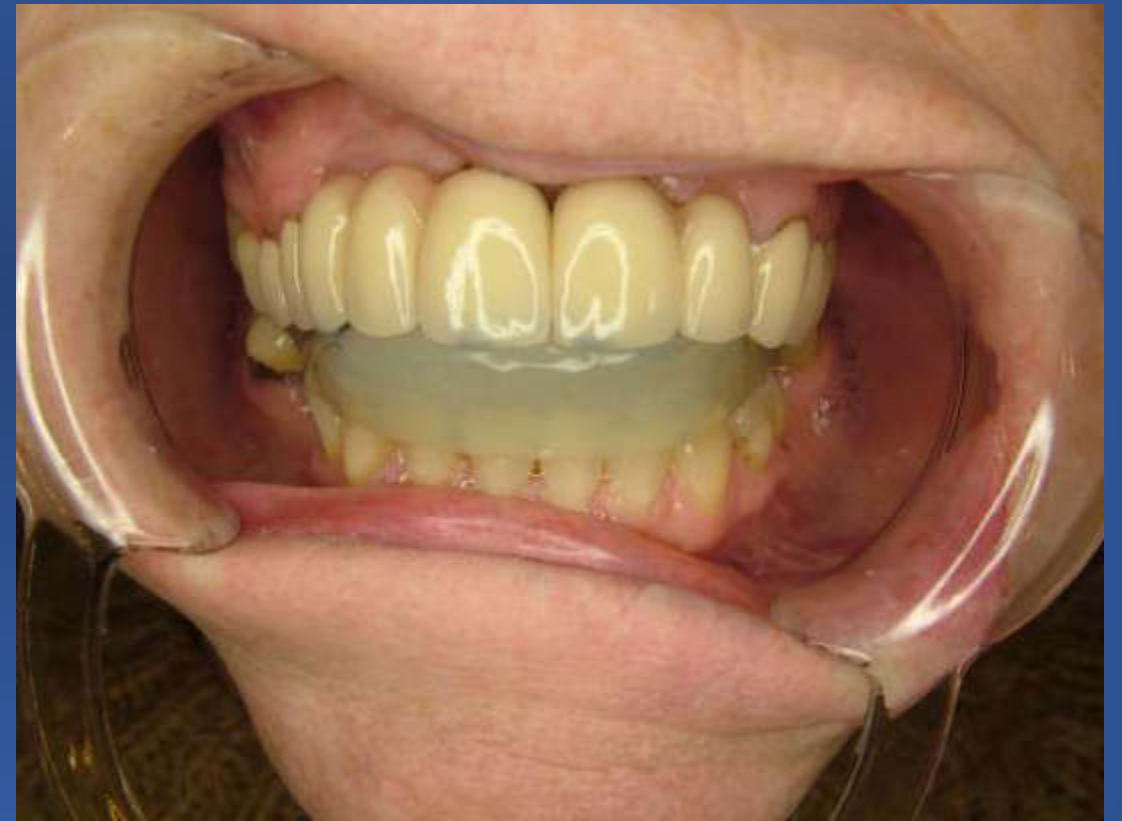E-J TMA adjusted to even posterior occlusion with smooth shallow Anterior Guidance



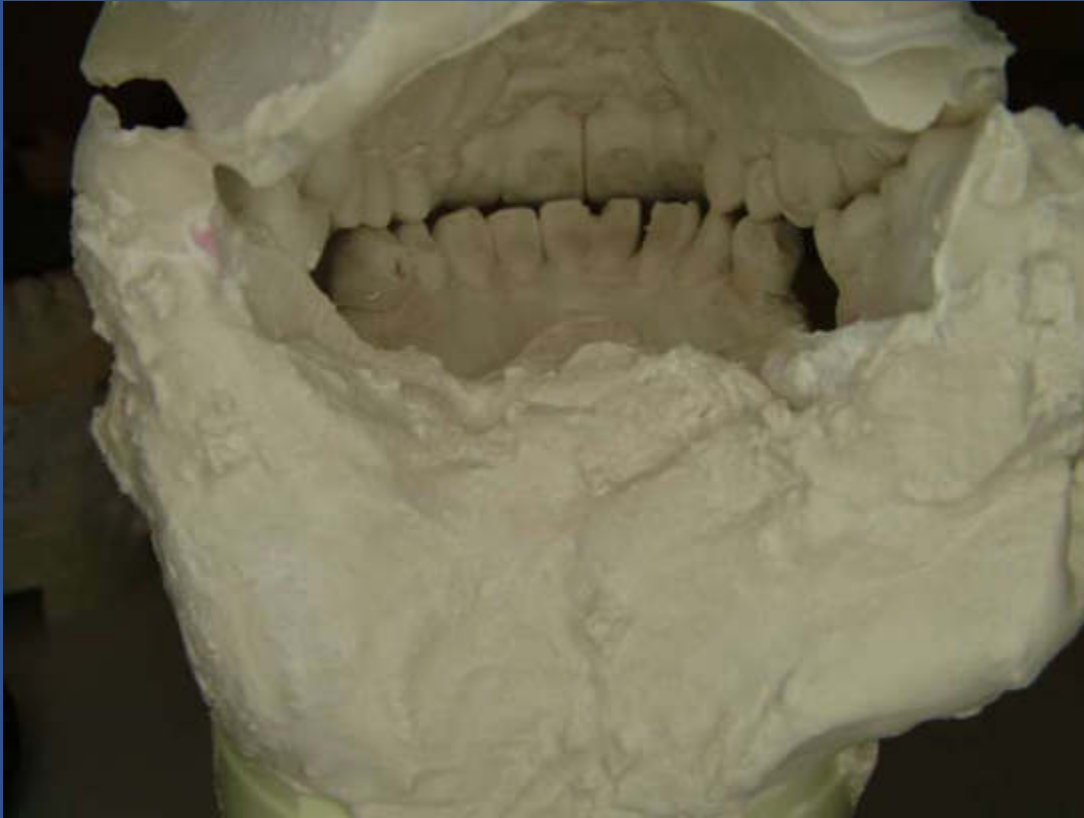
N.B. Implant case, with Lyme Disease



LOWER RIGHT 6 EXTRACTED FOR SUSPECTED
NICO CAVITATIONS, HARBOURING BORRELIA
POOR OCCLUSAL FUNCTION ADDRESSED WITH TMA
NB UNDER CARE IN GERMANY FOR LYME DISEASE

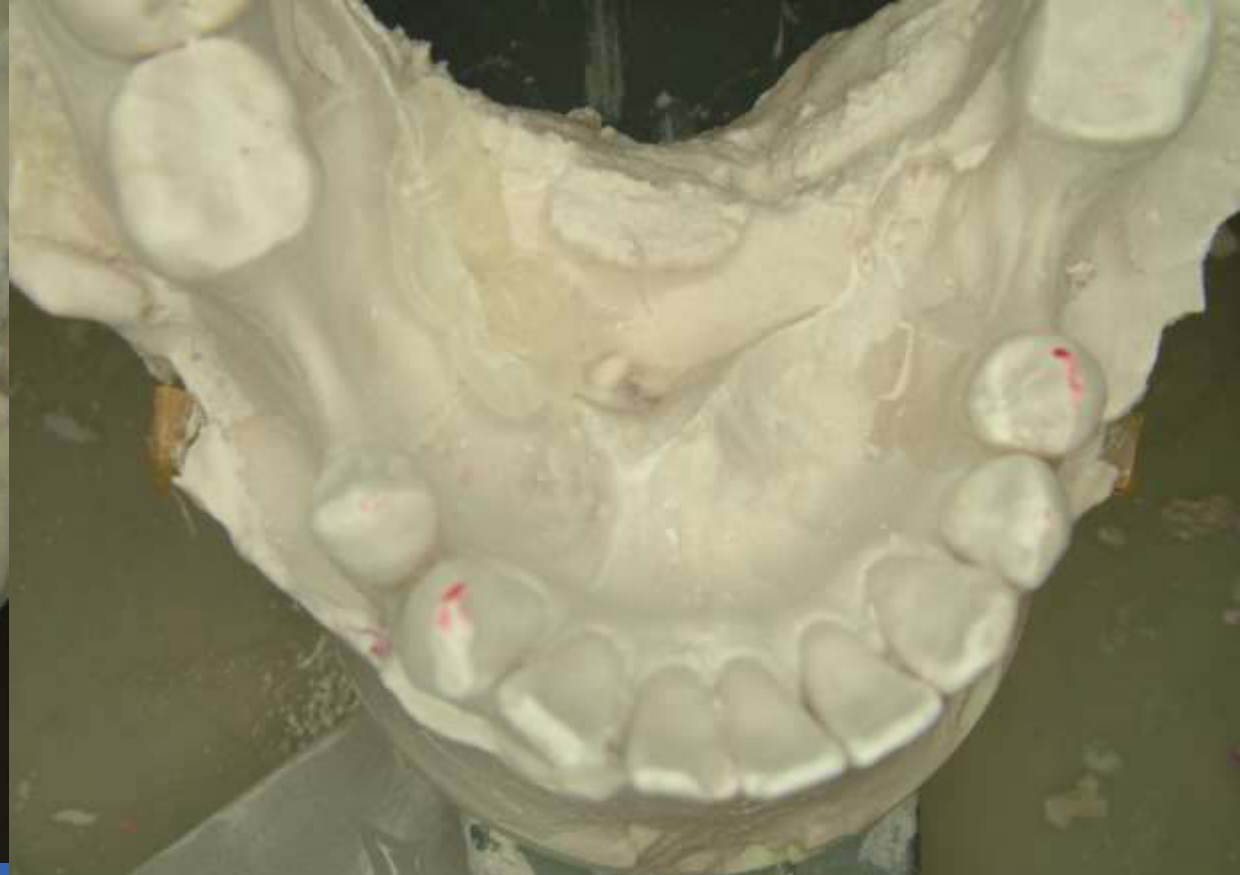
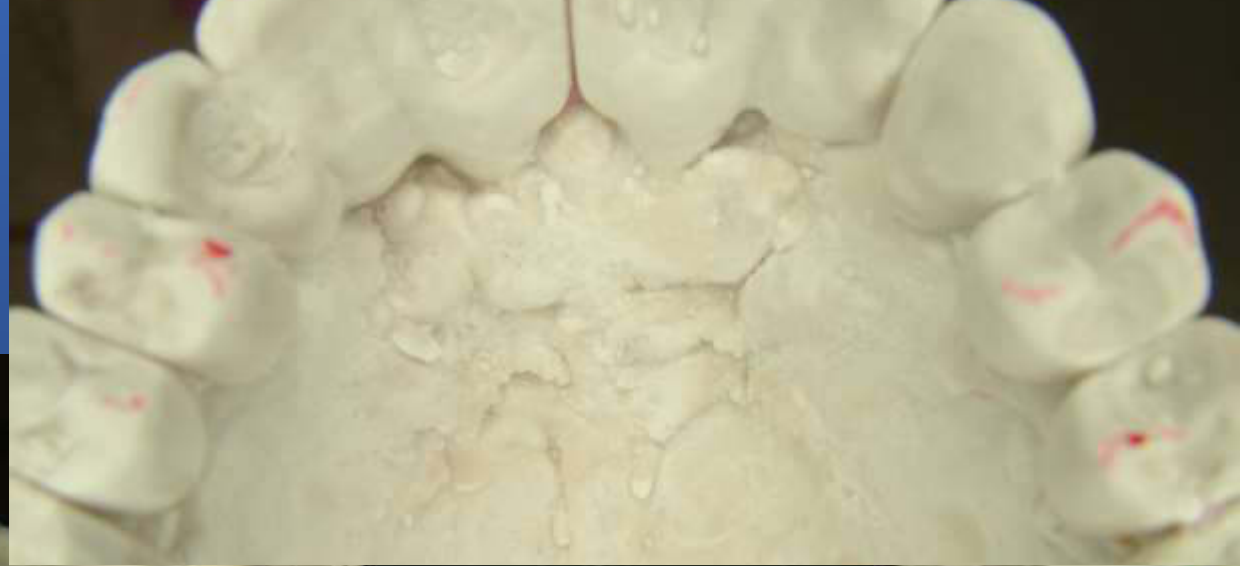
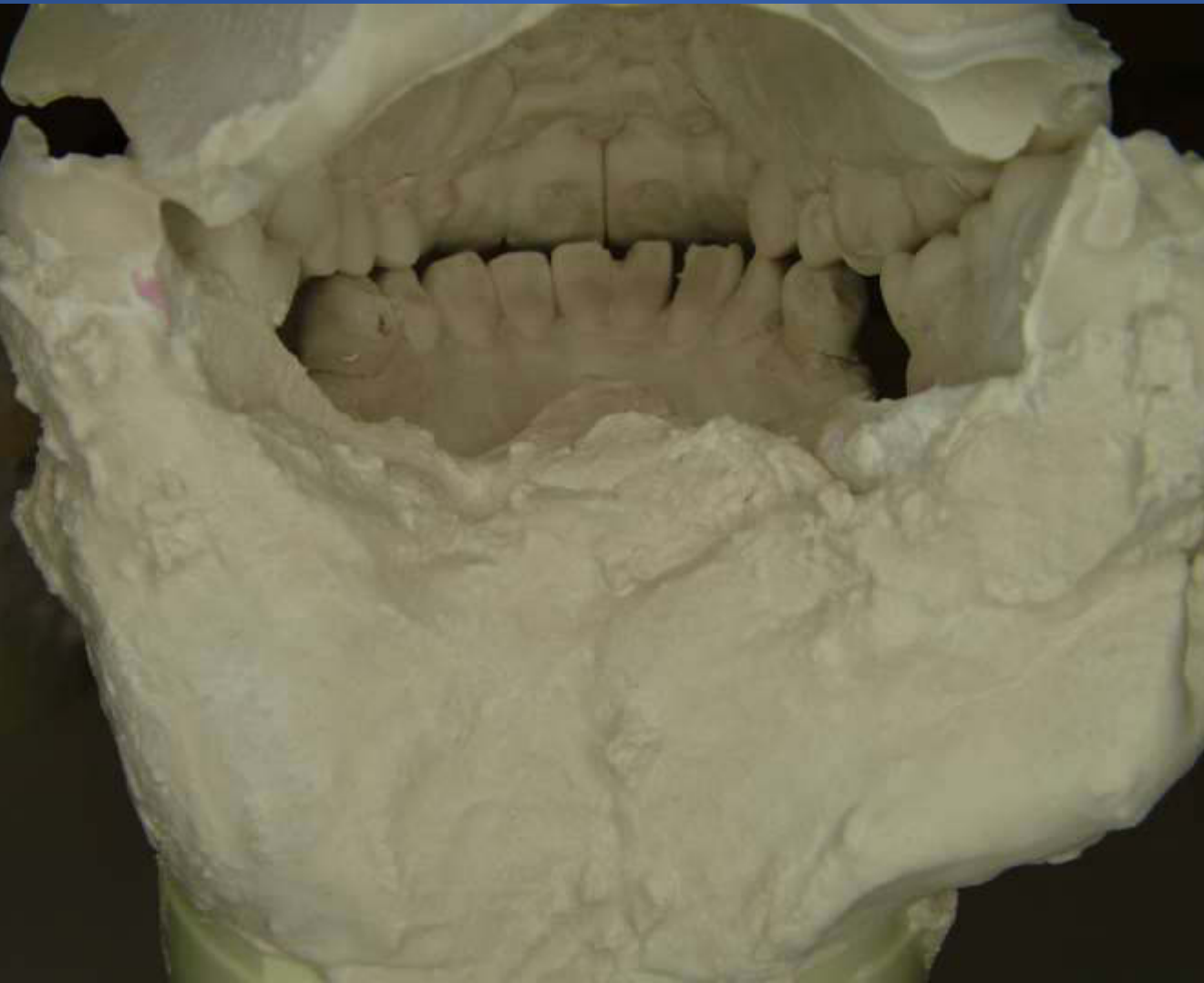NB Anterior implants

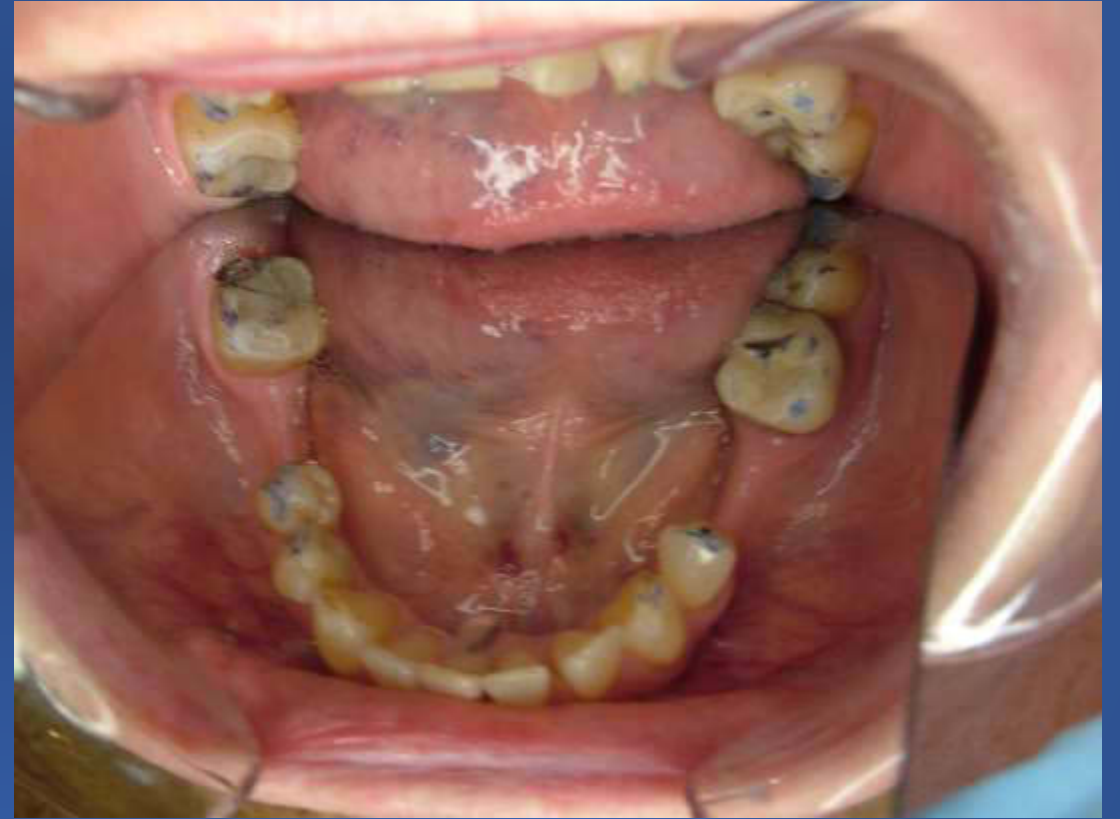
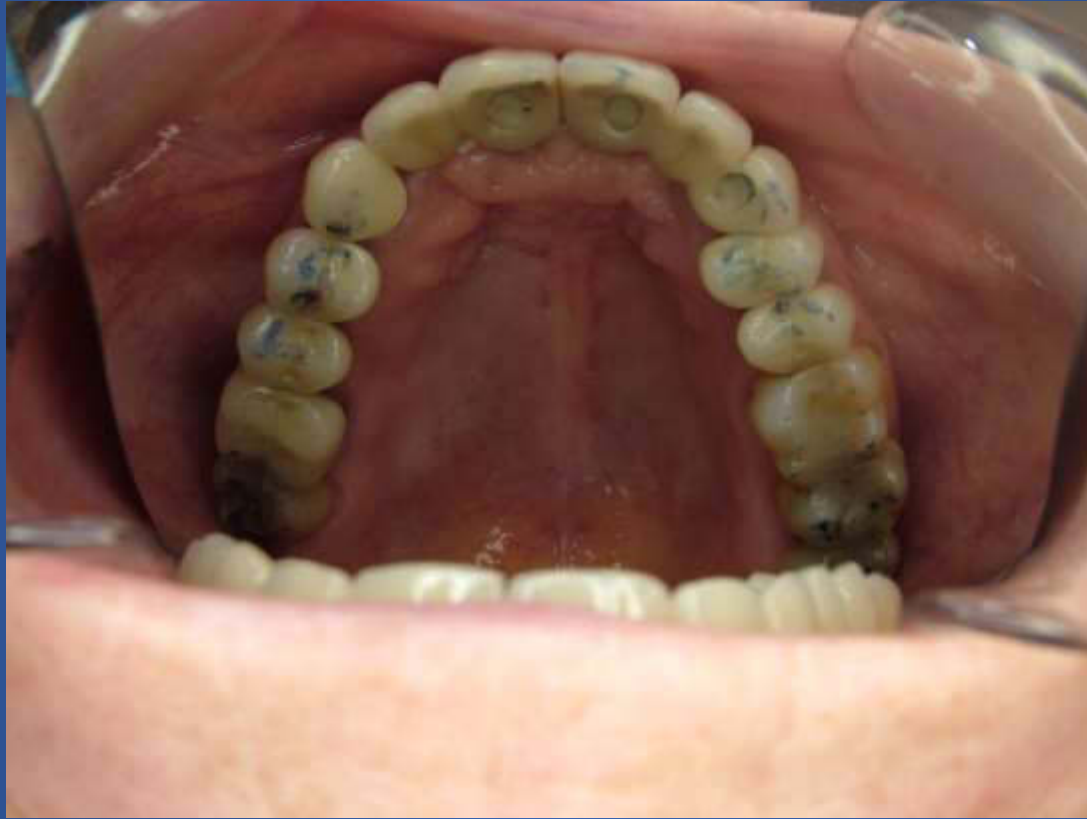

- Referred by Lyme disease clinic to Dr Iain Smith
- Poor Centric Relation Occlusion and occlusal mechanics
- TMA treatment to alleviate any myofascial pain, and stabilize upper cervical vertebrae
- Daily severe migraine type headaches, worse since implants were placed

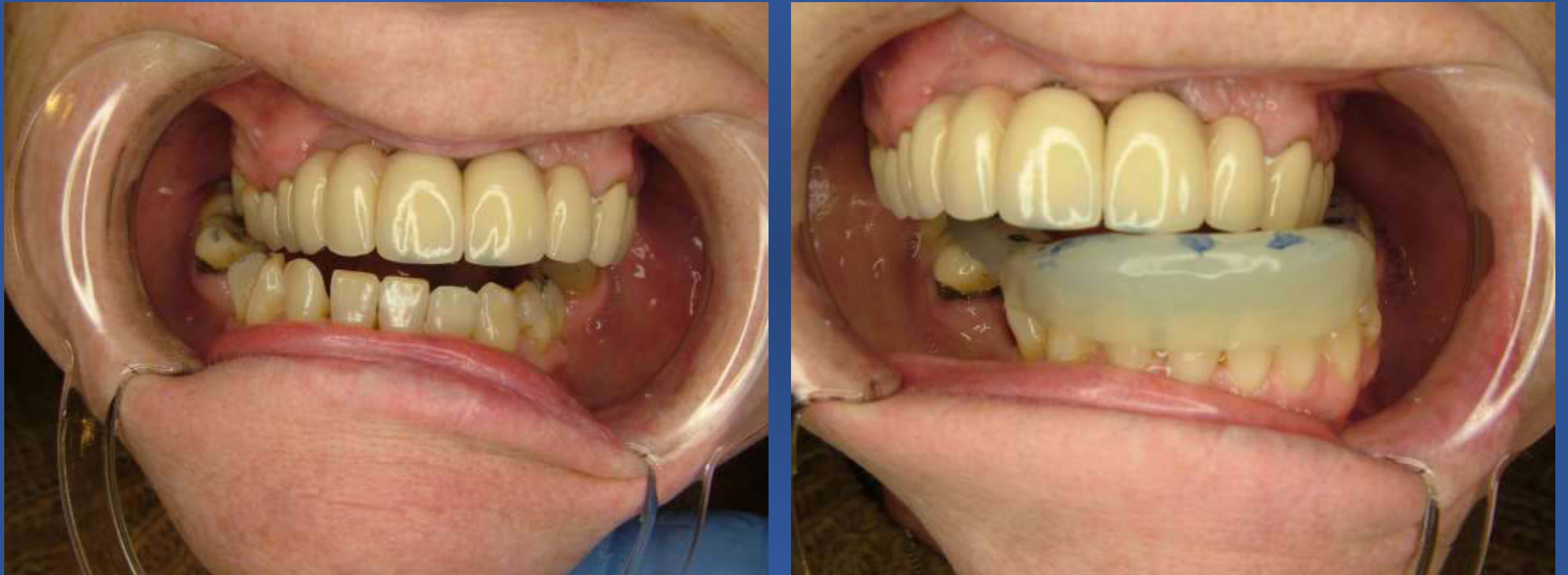Very nice implants, poor
occlusal function



N.B. Implant case, with Lyme Disease



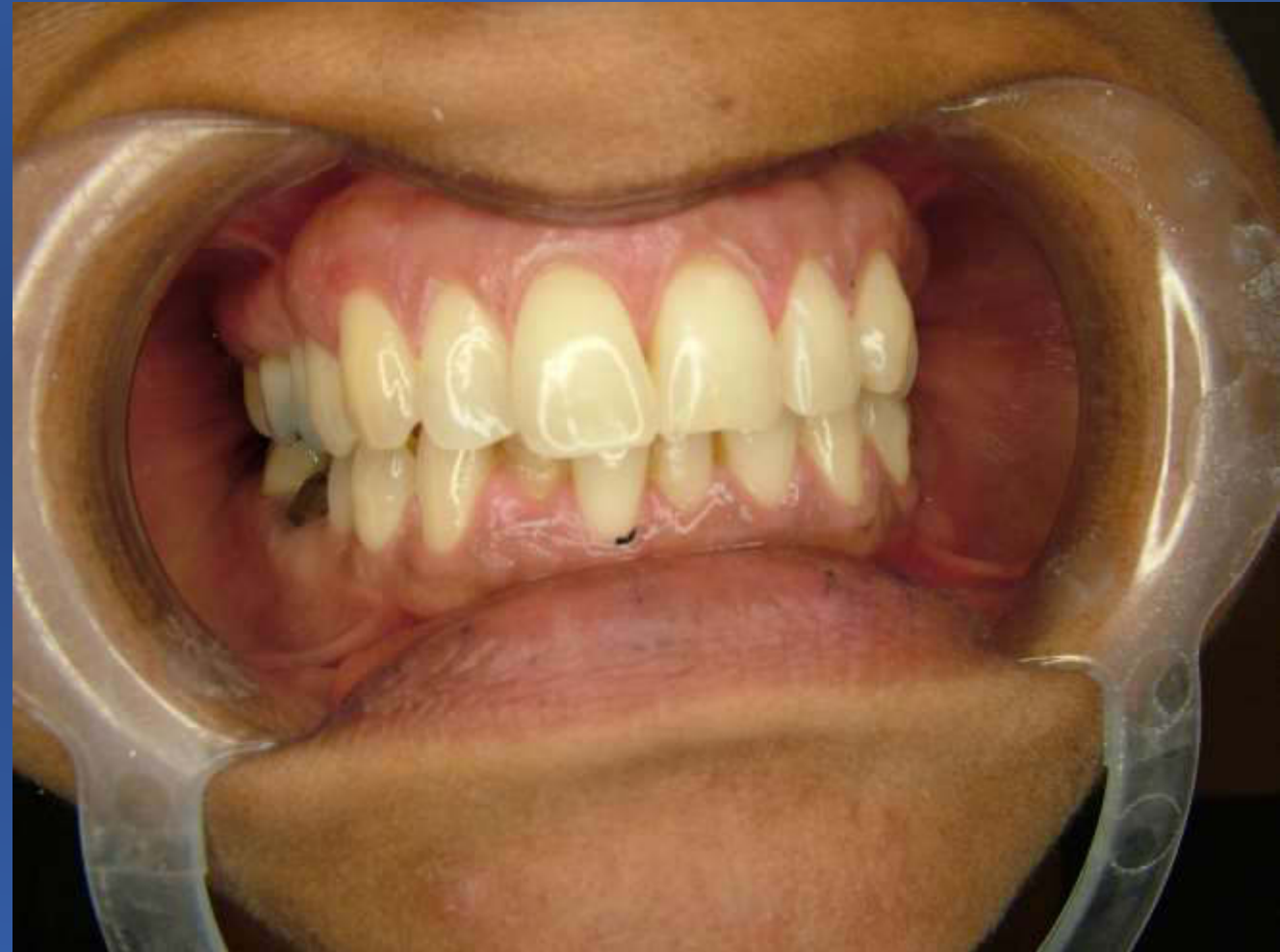N.B. Implant case, with Lyme Disease



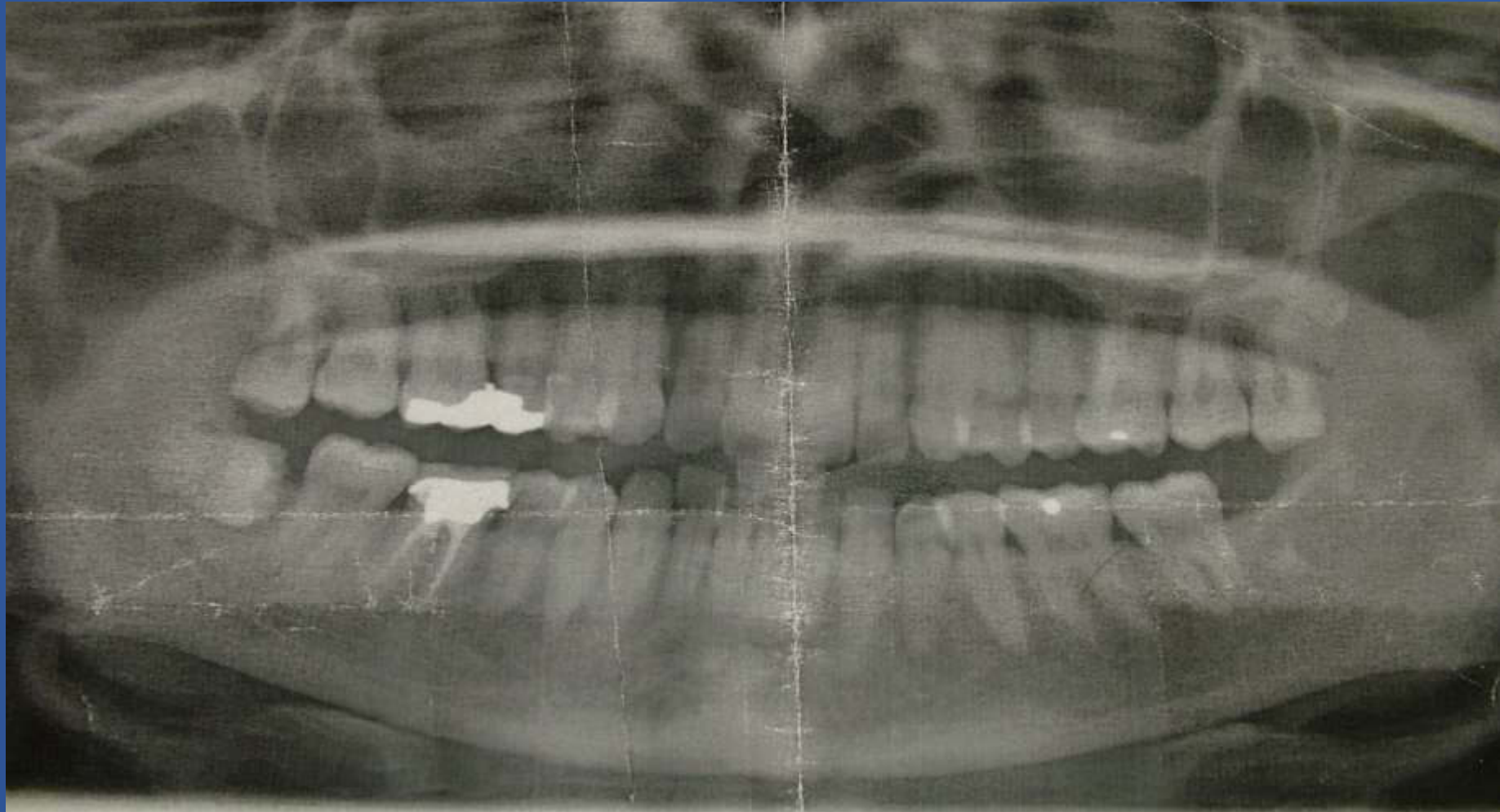TMA RESTORES CRO OCCLUSION AND LATERAL ANTERIOR GUIDANCE
Increased energy levels, less headaches

NF, referred Functional Dental opinion

- 20 years history of head and neck pain
- Diagnosed CCJS
- Made worse in 2017, with inappropriate neck manipulation, hence consulted Dr Smith
- 10 months AO treatment shown marked improvement
- But....



OPG in protruded position

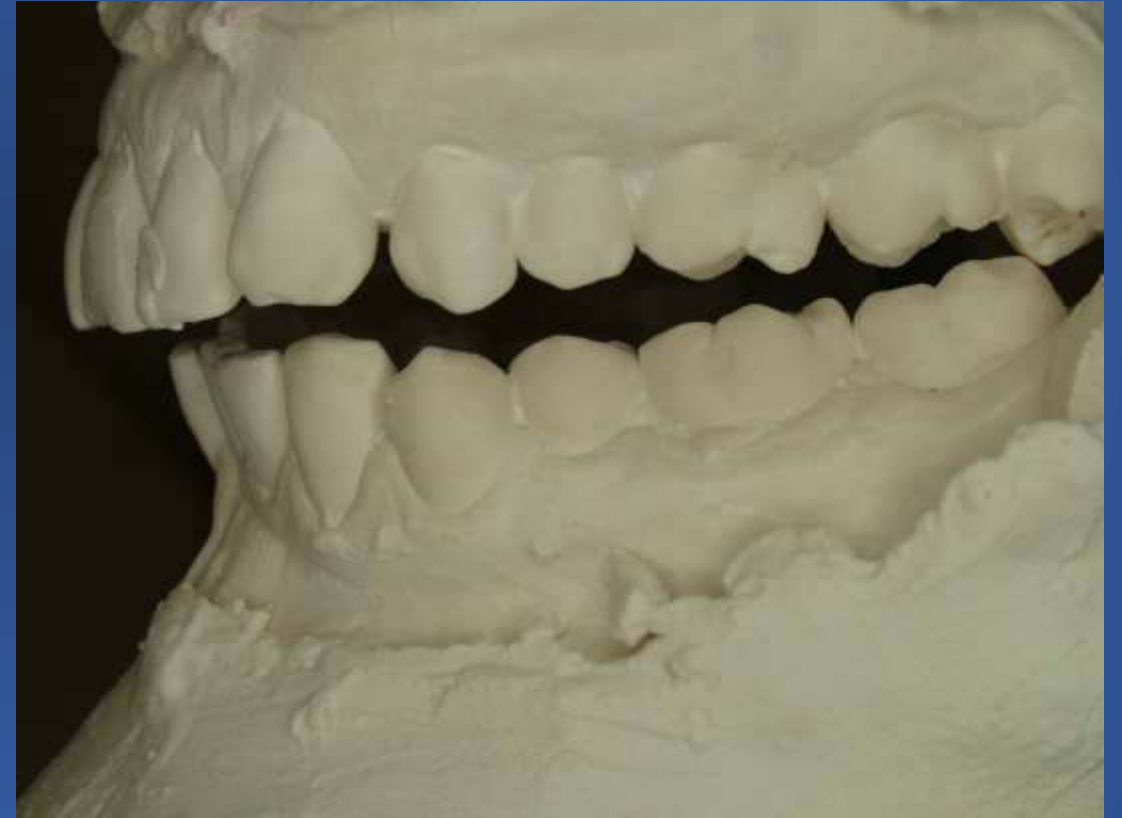
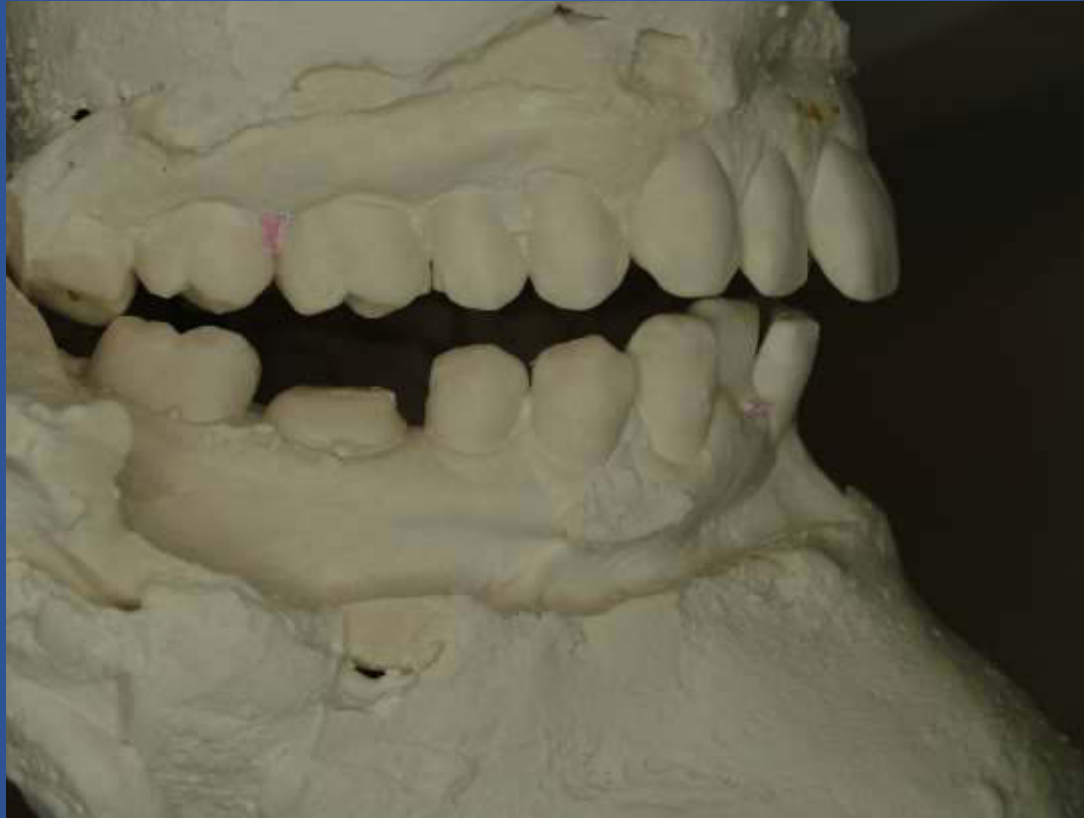
Practitioner : UM

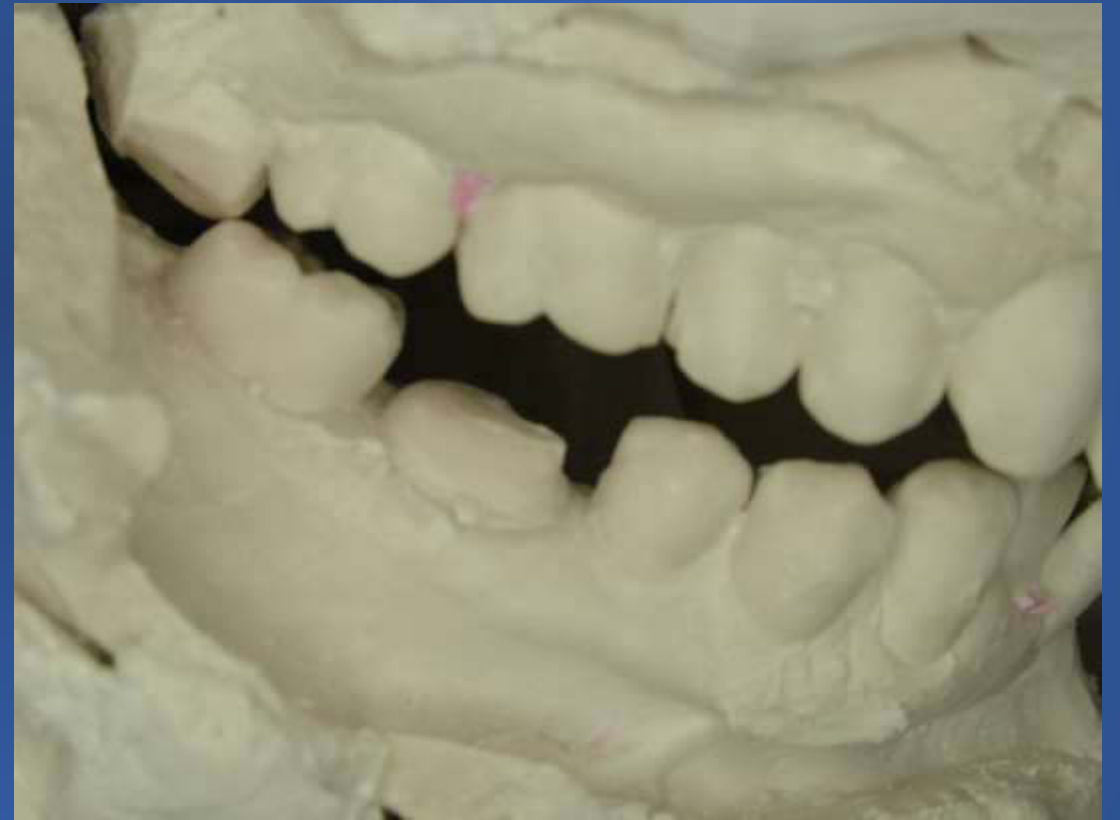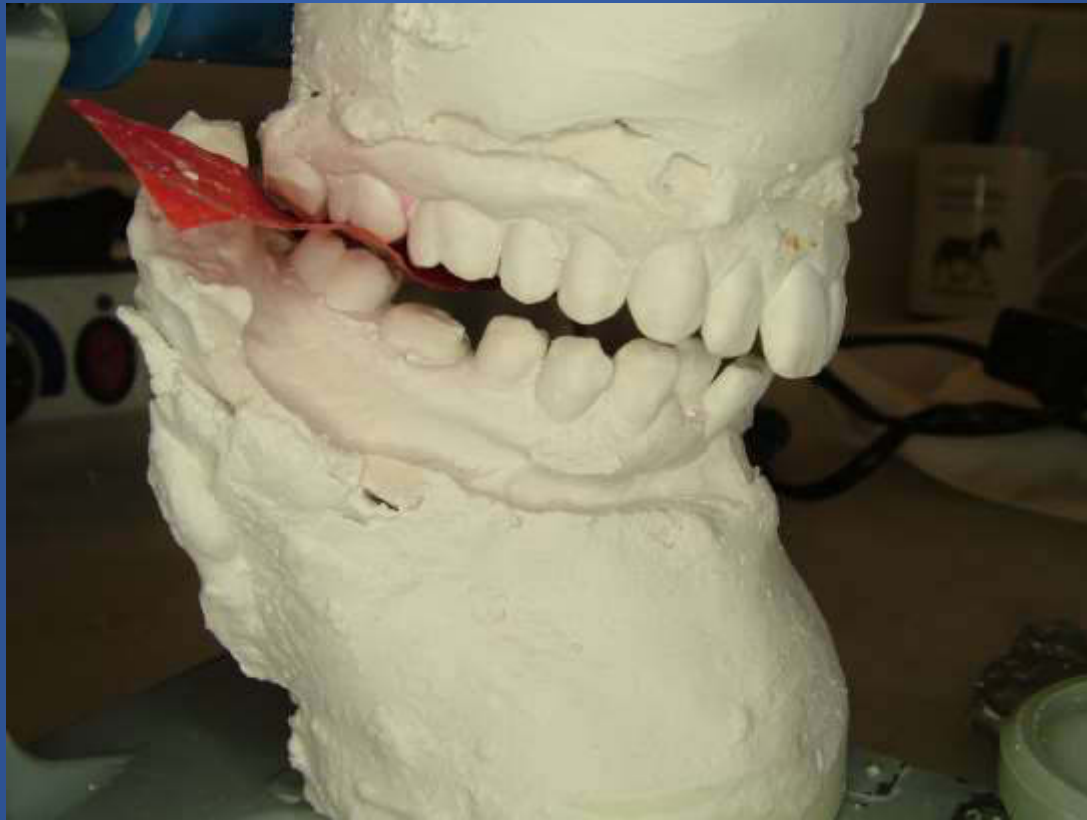Picture : XP

Date : 20/01/2017

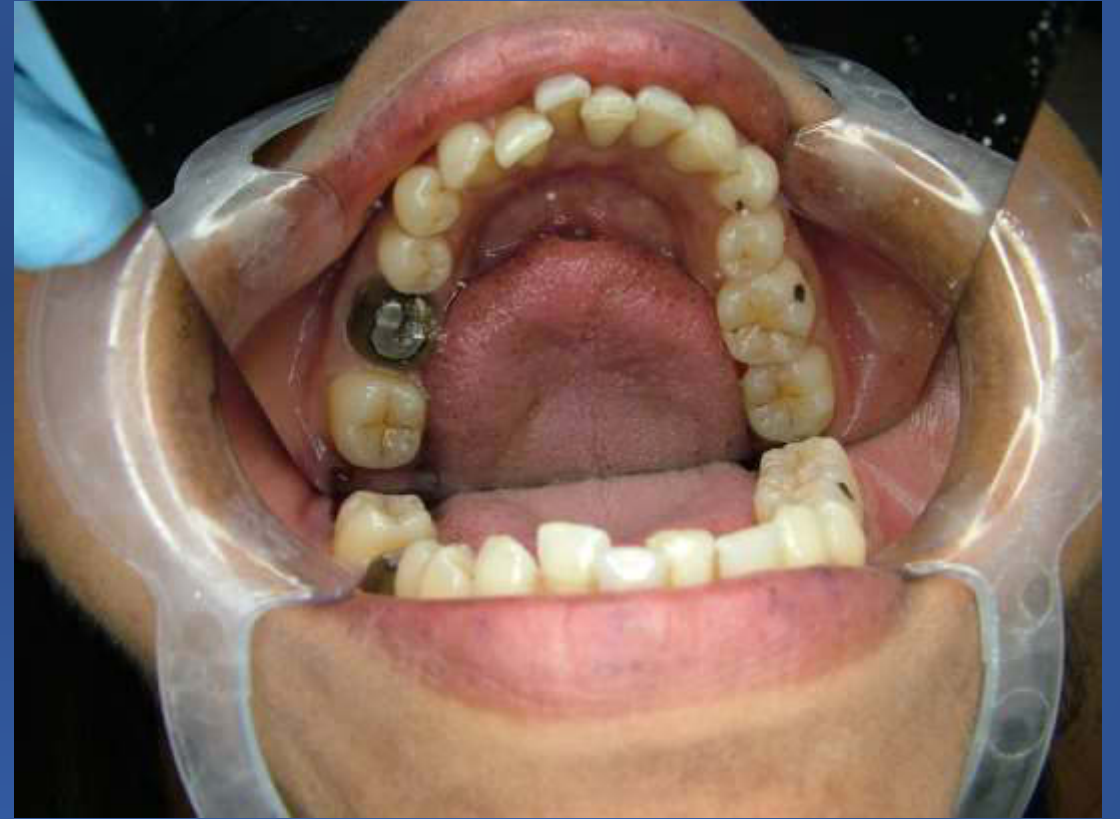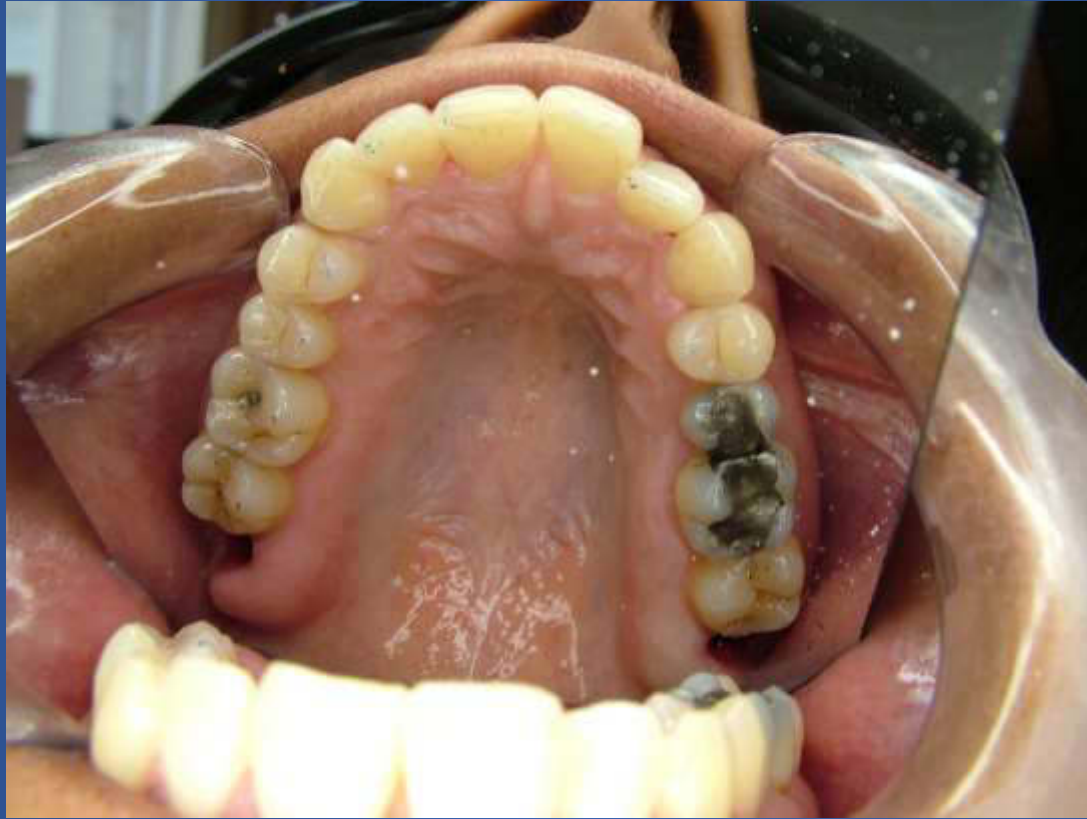
NF, CRO interferences upper WISDOM TEETH



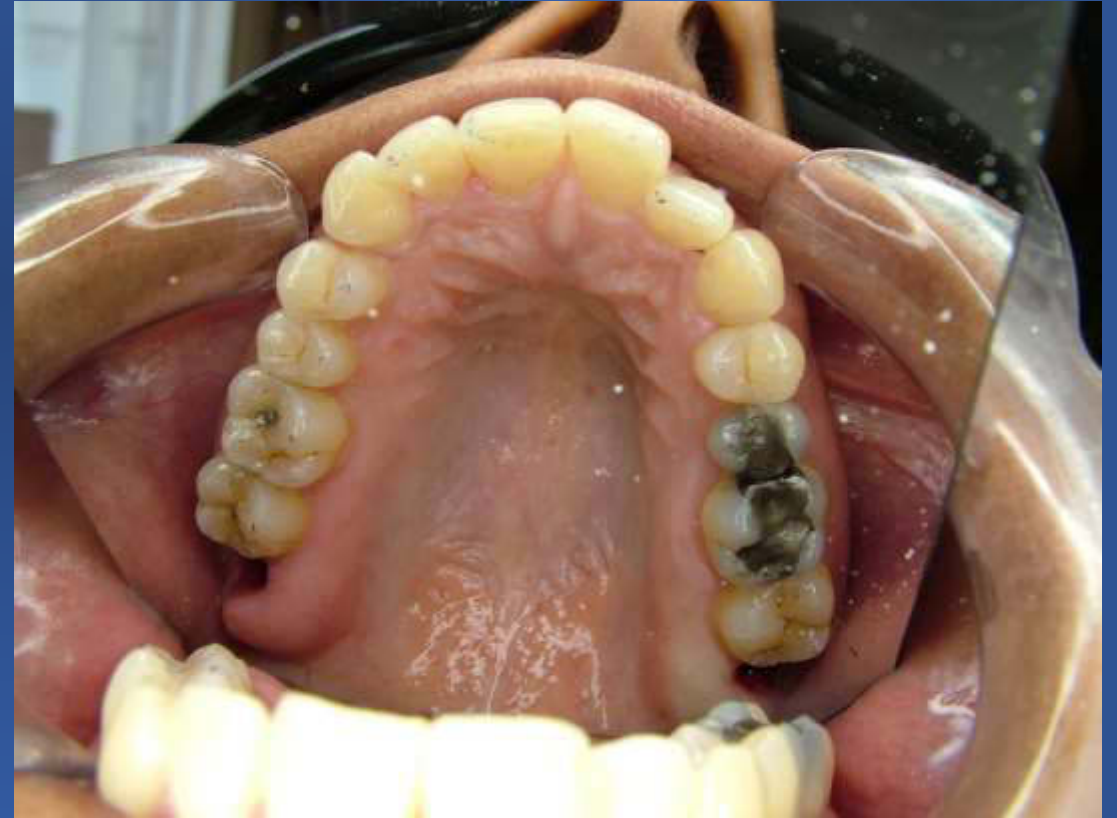
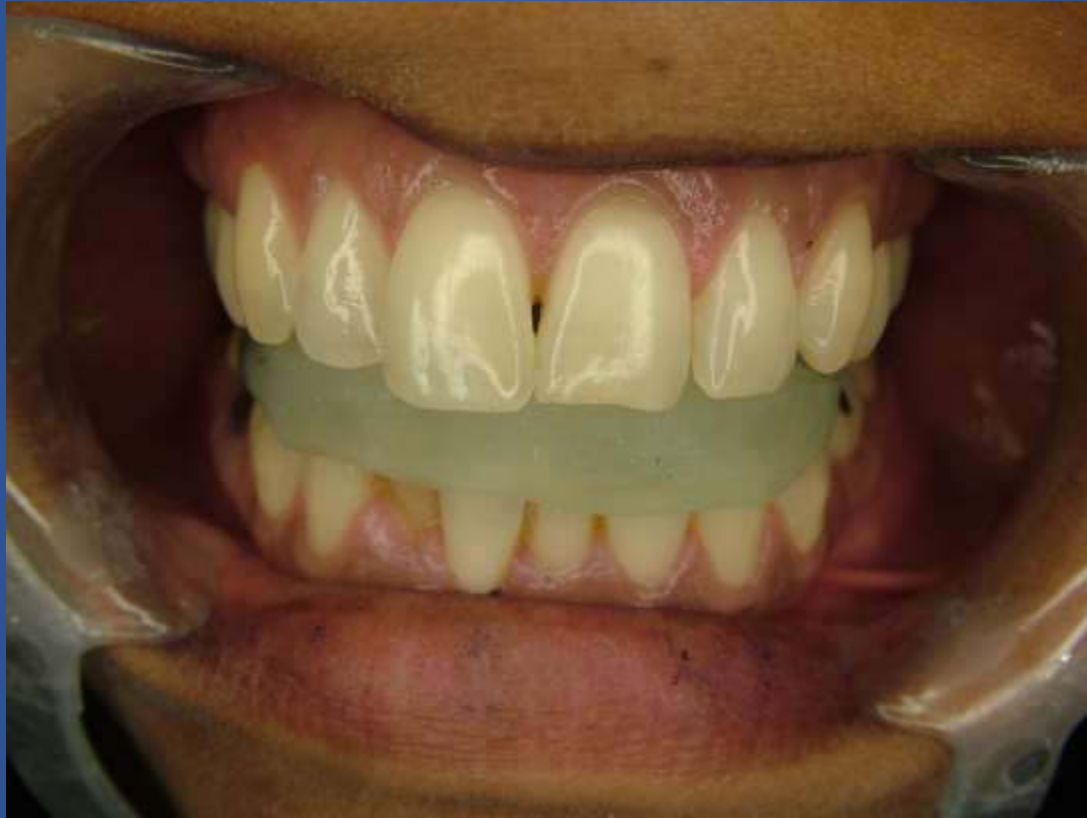NF upper 8s over-erupted & CRO interference to mandibular closure



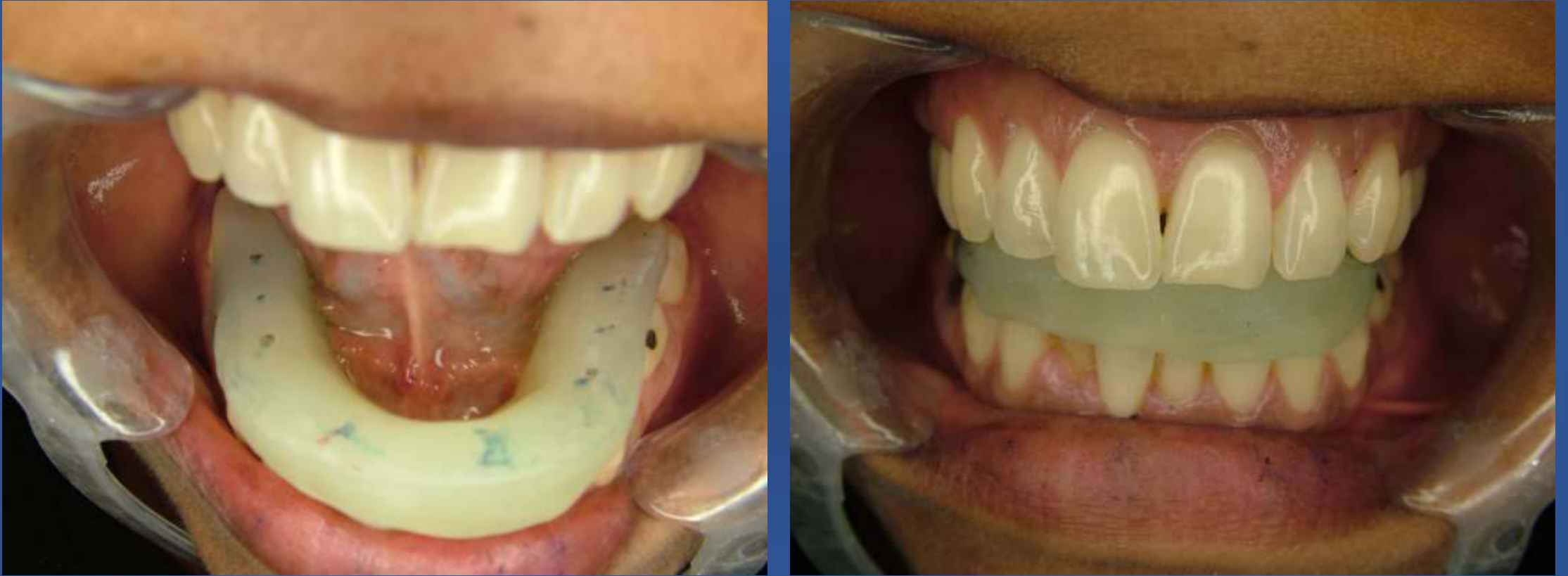NF, Upper 8s removed FIRST, then TMA fitted



Upper 8s removed, TMA fitted, the same day
22/7/20

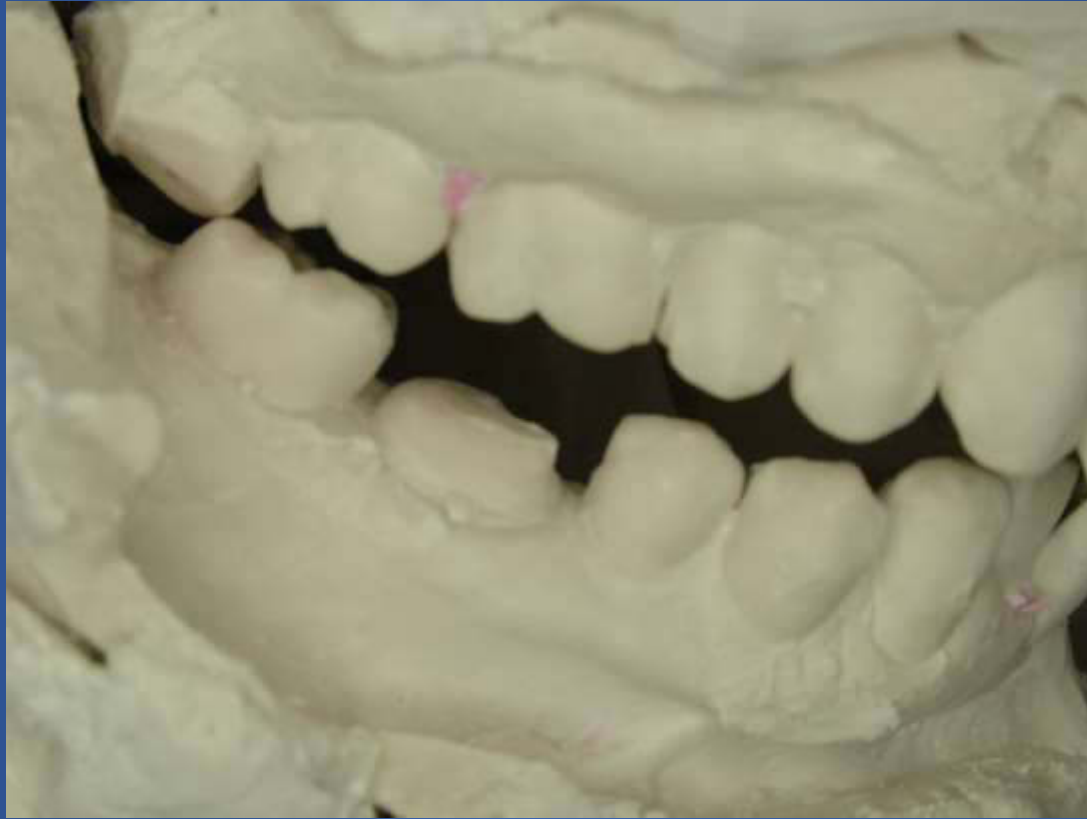

NF, TMA adjusted

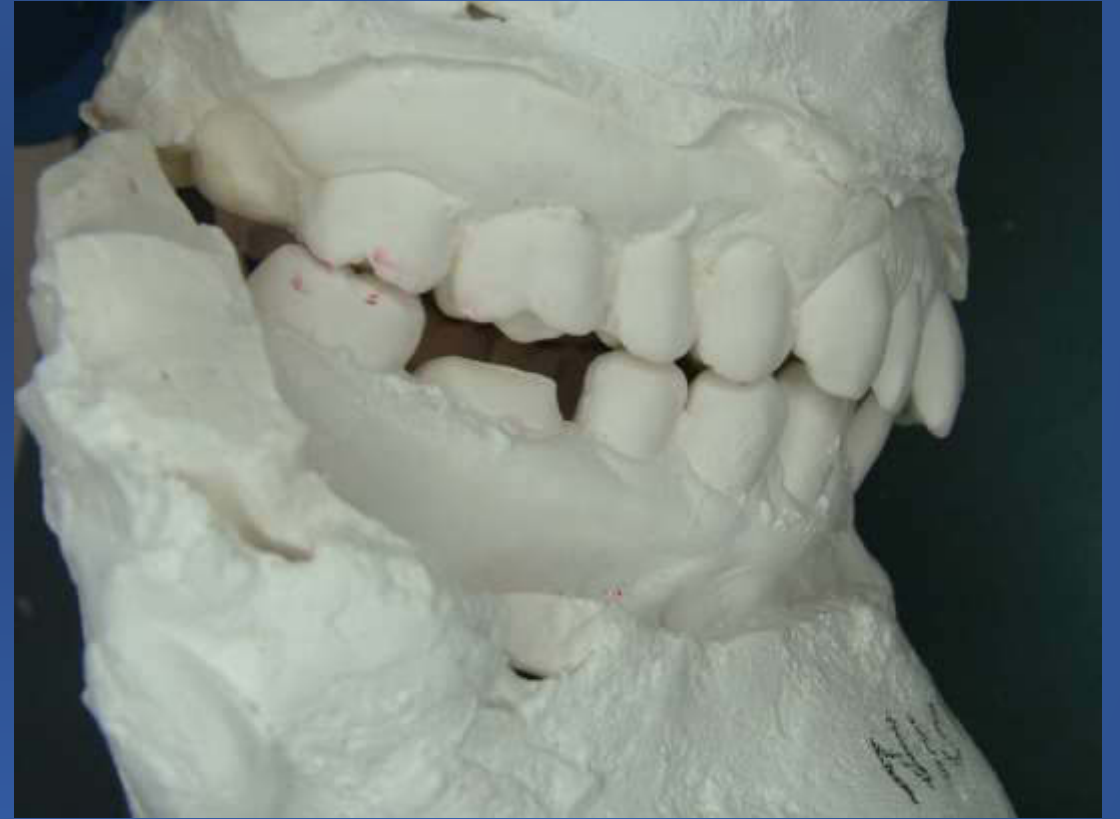

Immediate improvement, which is still requiring post-adaptation adjustments with combined AO and Occlusal treatment

NF, Study models, one month after extractions

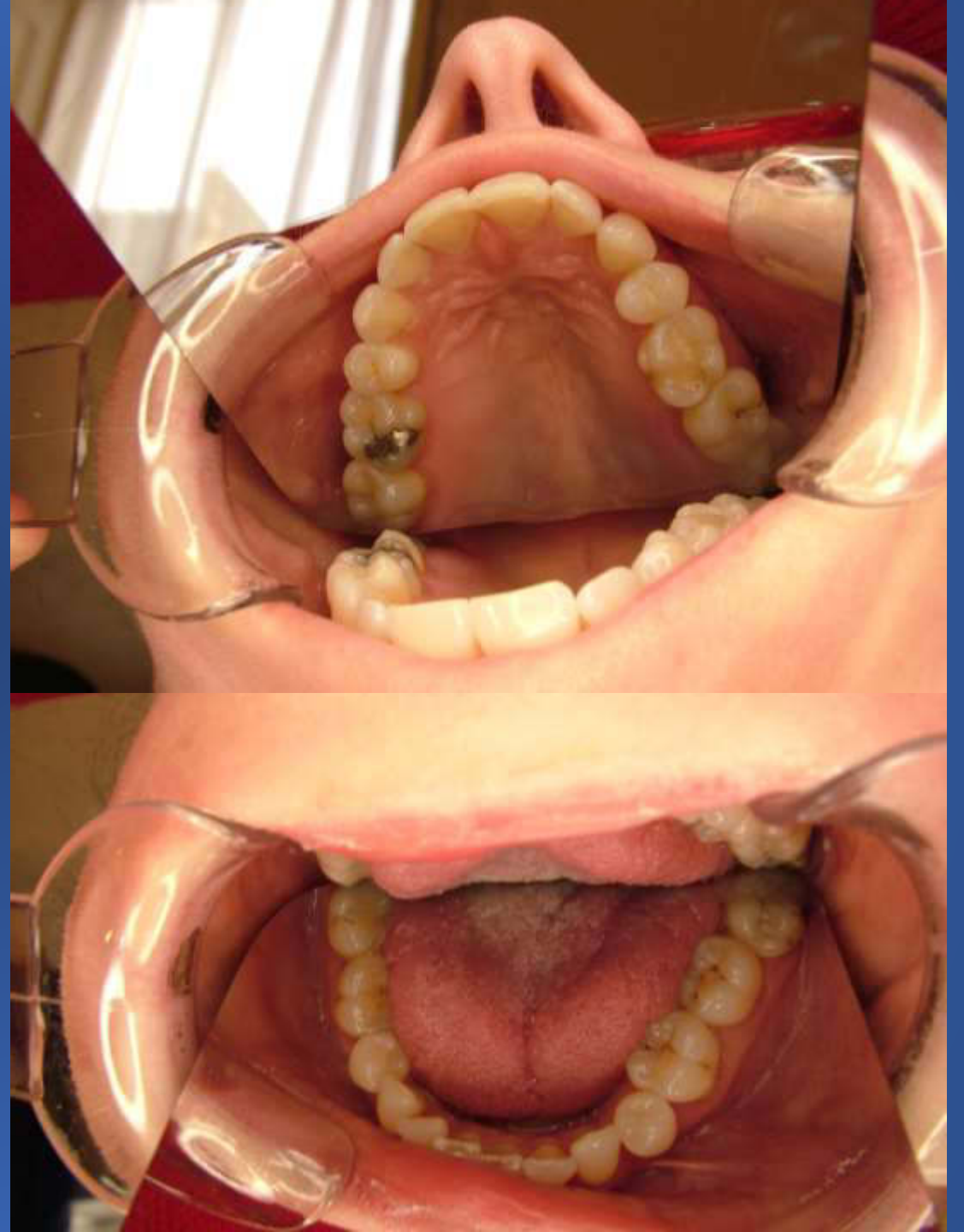


BEFORE EXTRACTIONS

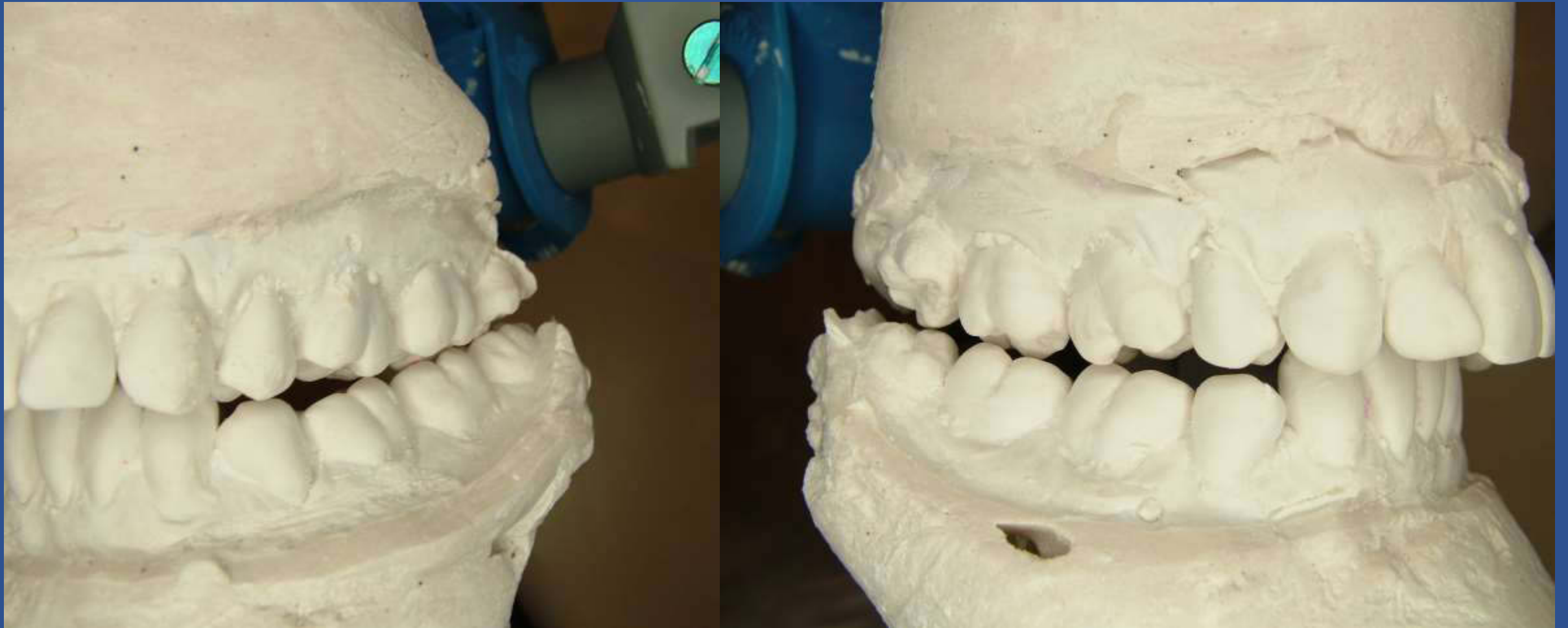


AFTER EXTRACTIONS

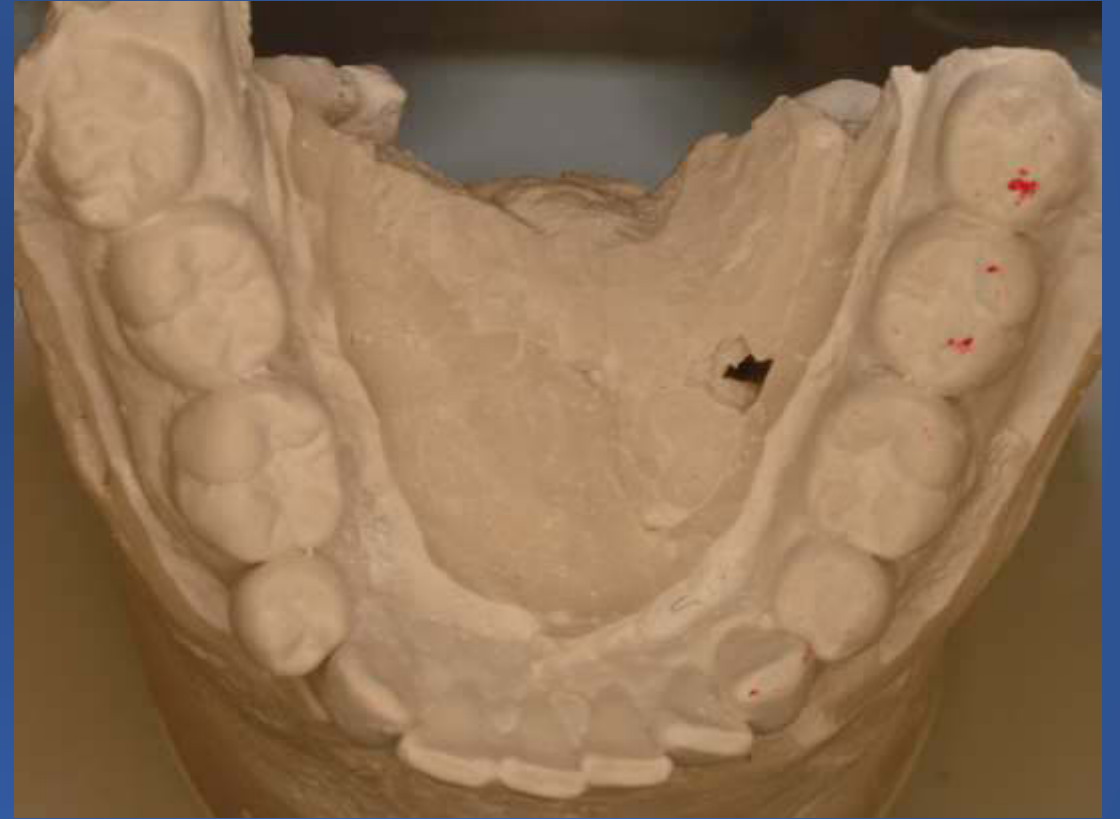
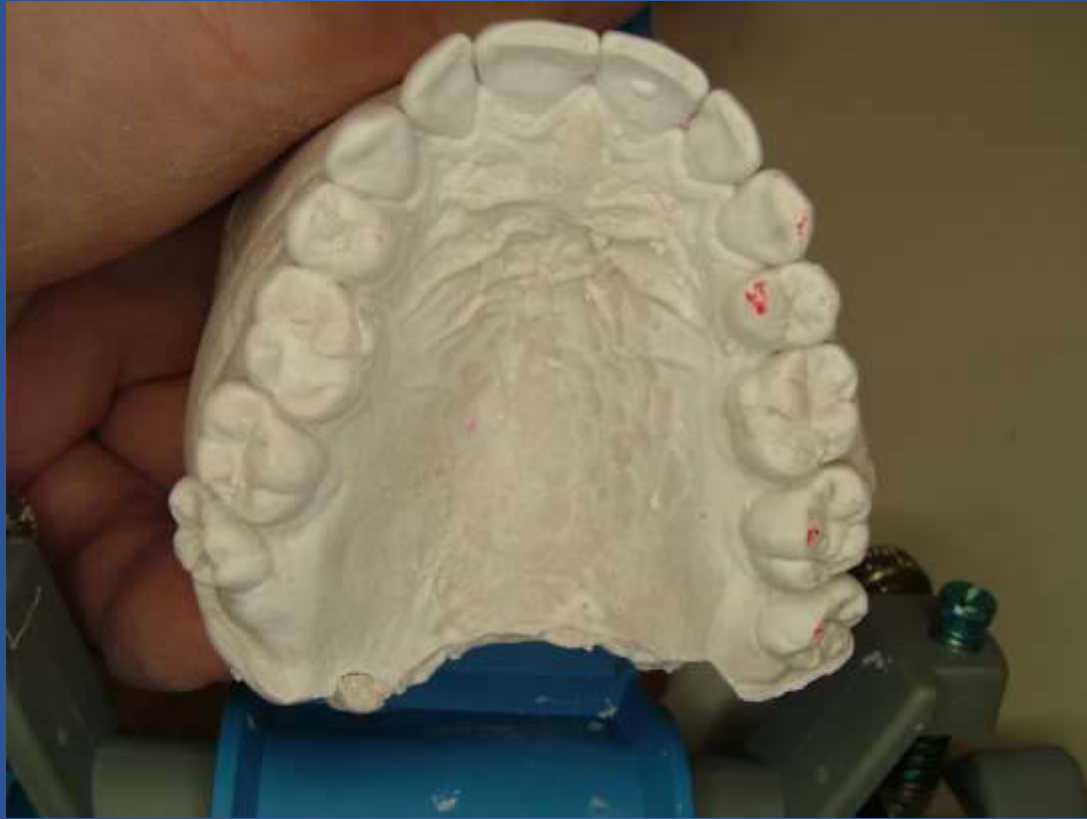Holly, EDS, CCJ, CCI,
IBS, POTS
Referred to
Dr. Iain Smith,
by her
Neurosurgeon
for
AO opinion



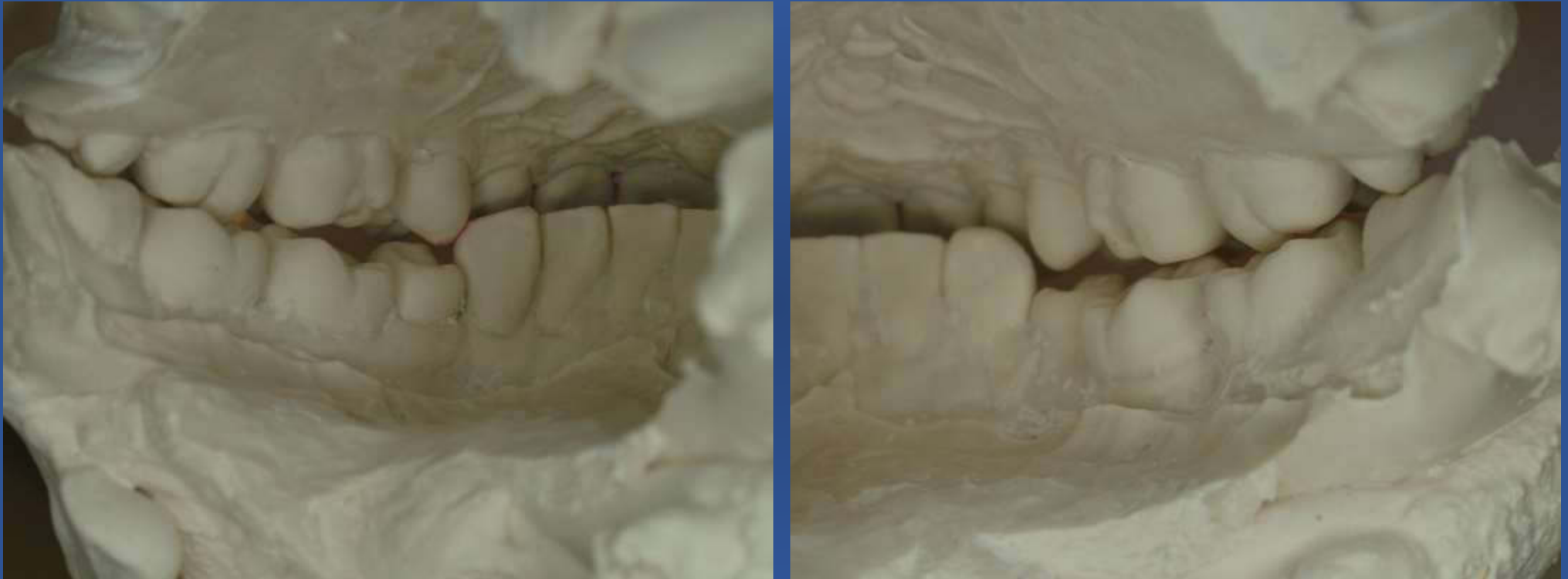Holly, Centric Relation Occlusion



1st contact CRO confirmed left side

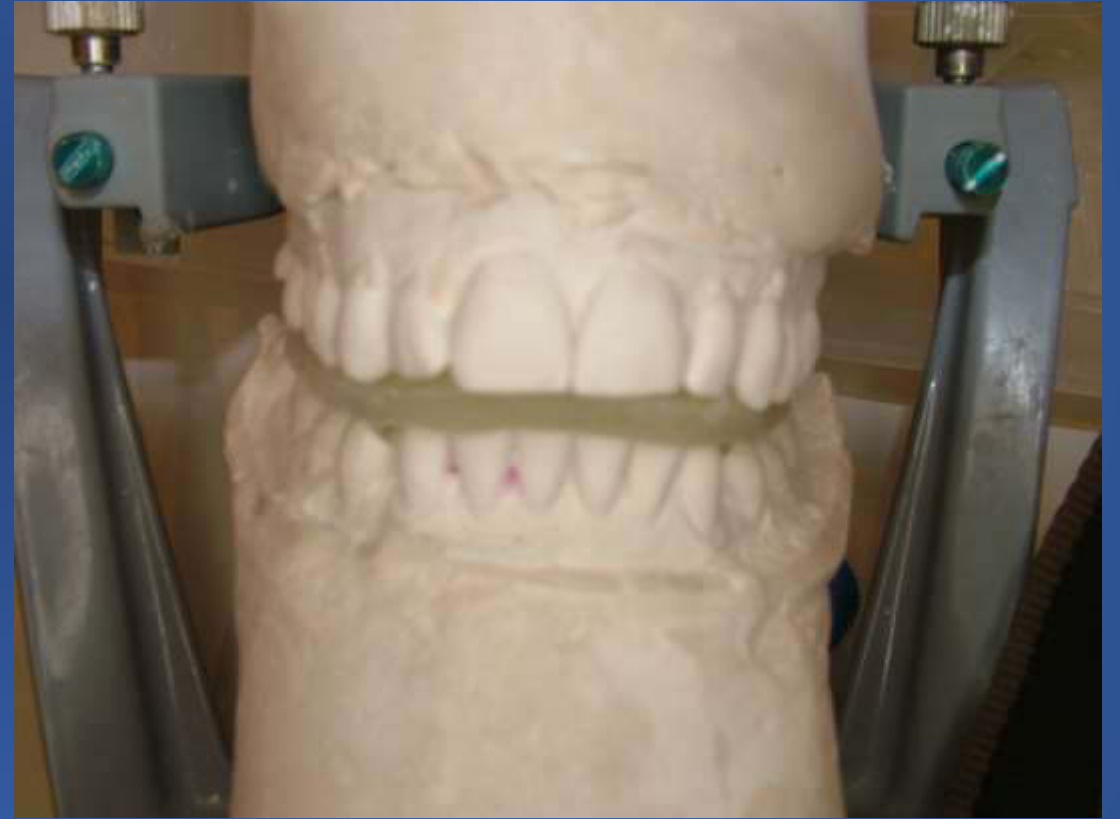
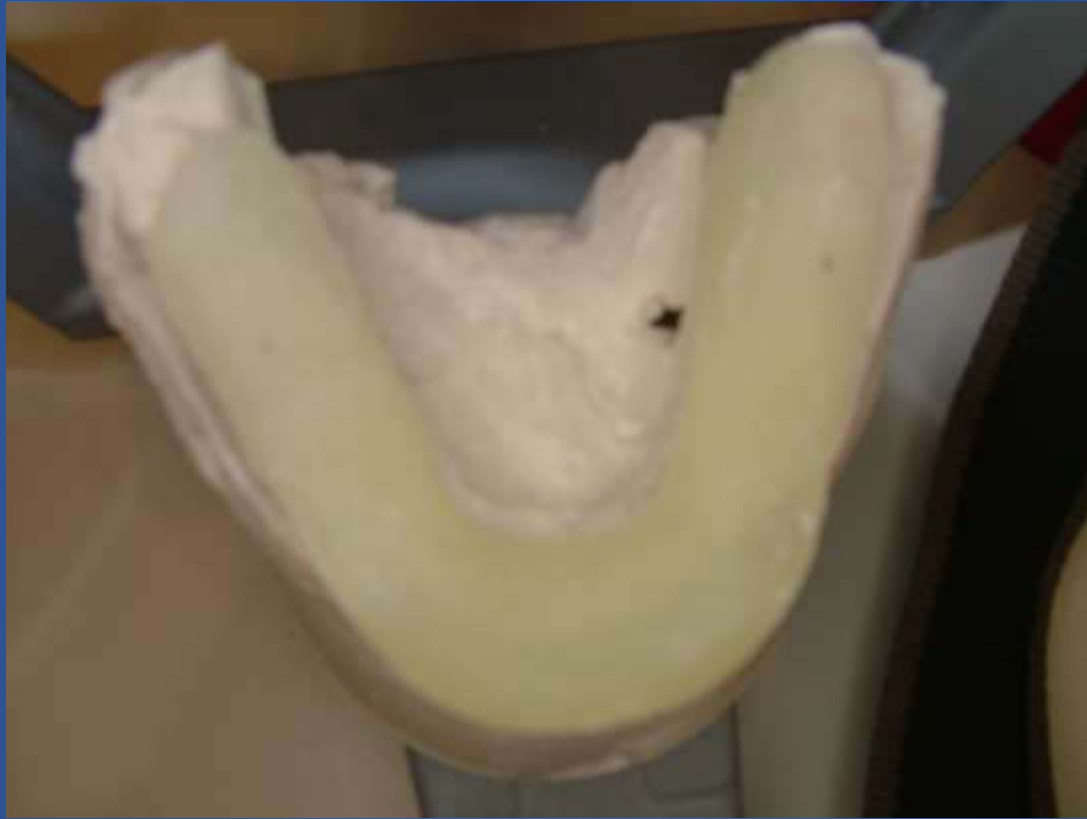
Holly, Centric Relation Occlusion, lingual view

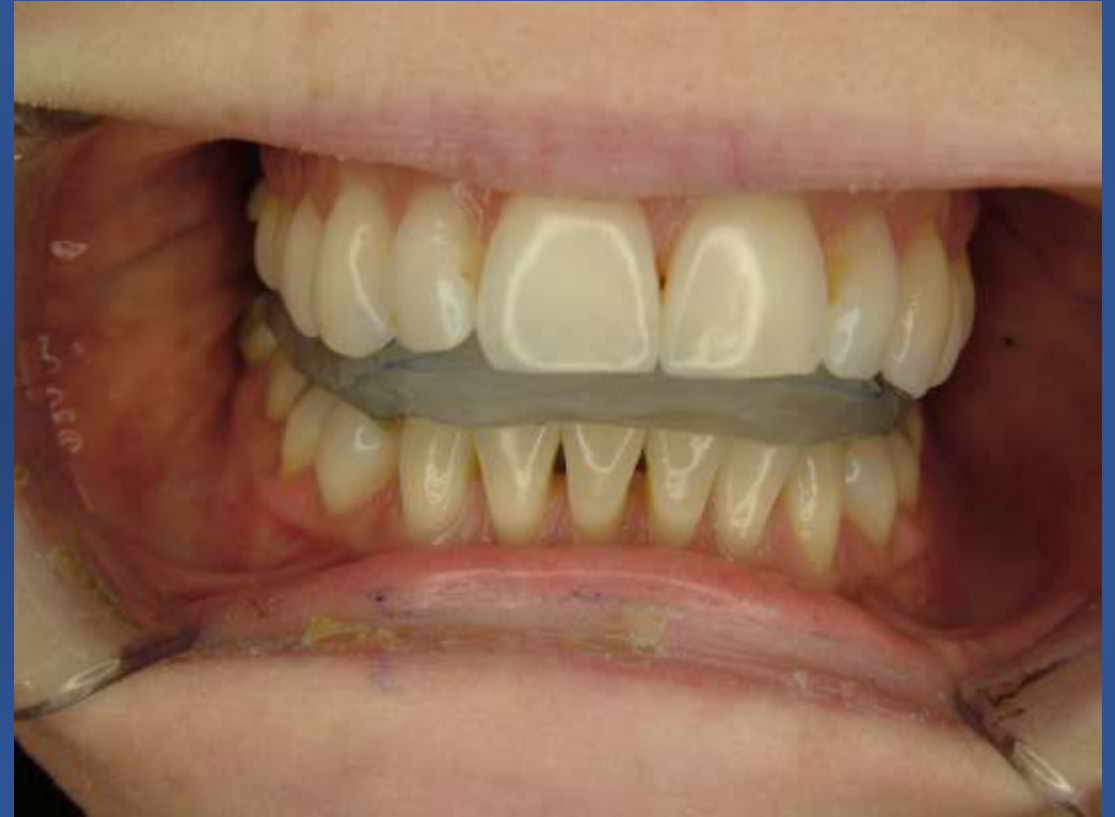
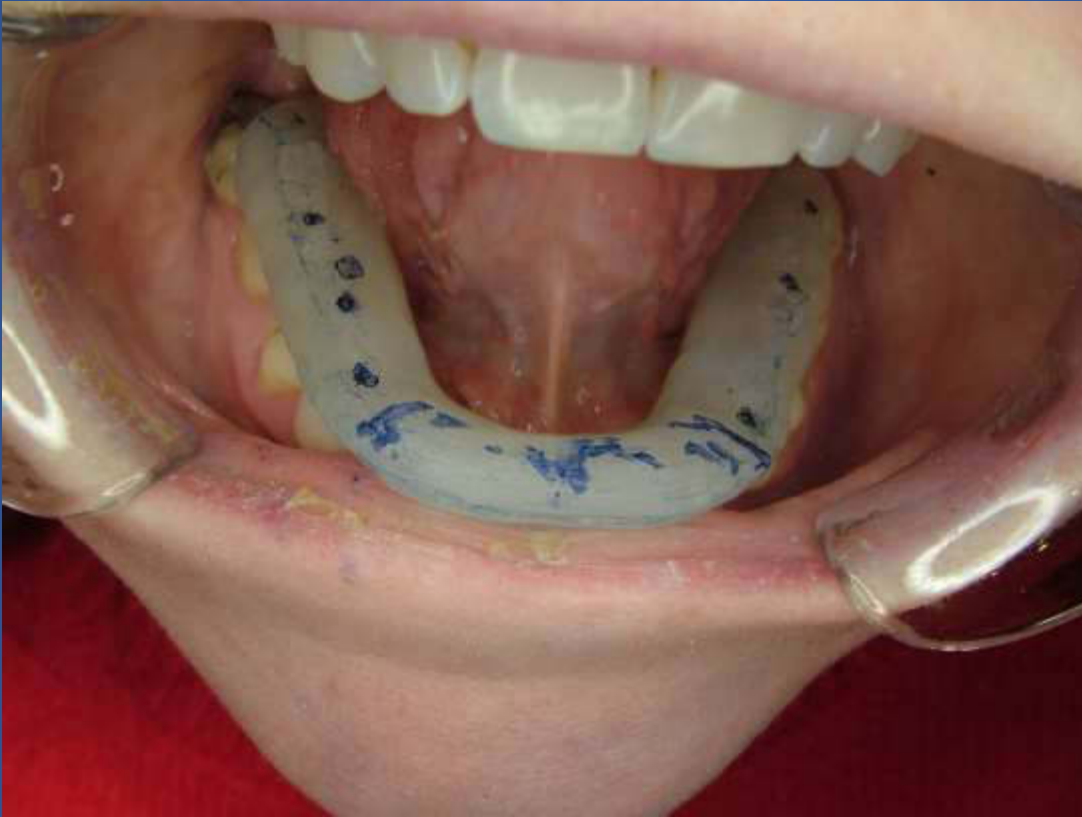
10 year severe pain History, since dislocating shoulder; Fitting during exam, severe constant pain, difficulty walking,
HAD a FIT during my muscle exam, when Hyoid palpated, ROM TMJ 35mm

TMA made on Anatomical Mounted Models

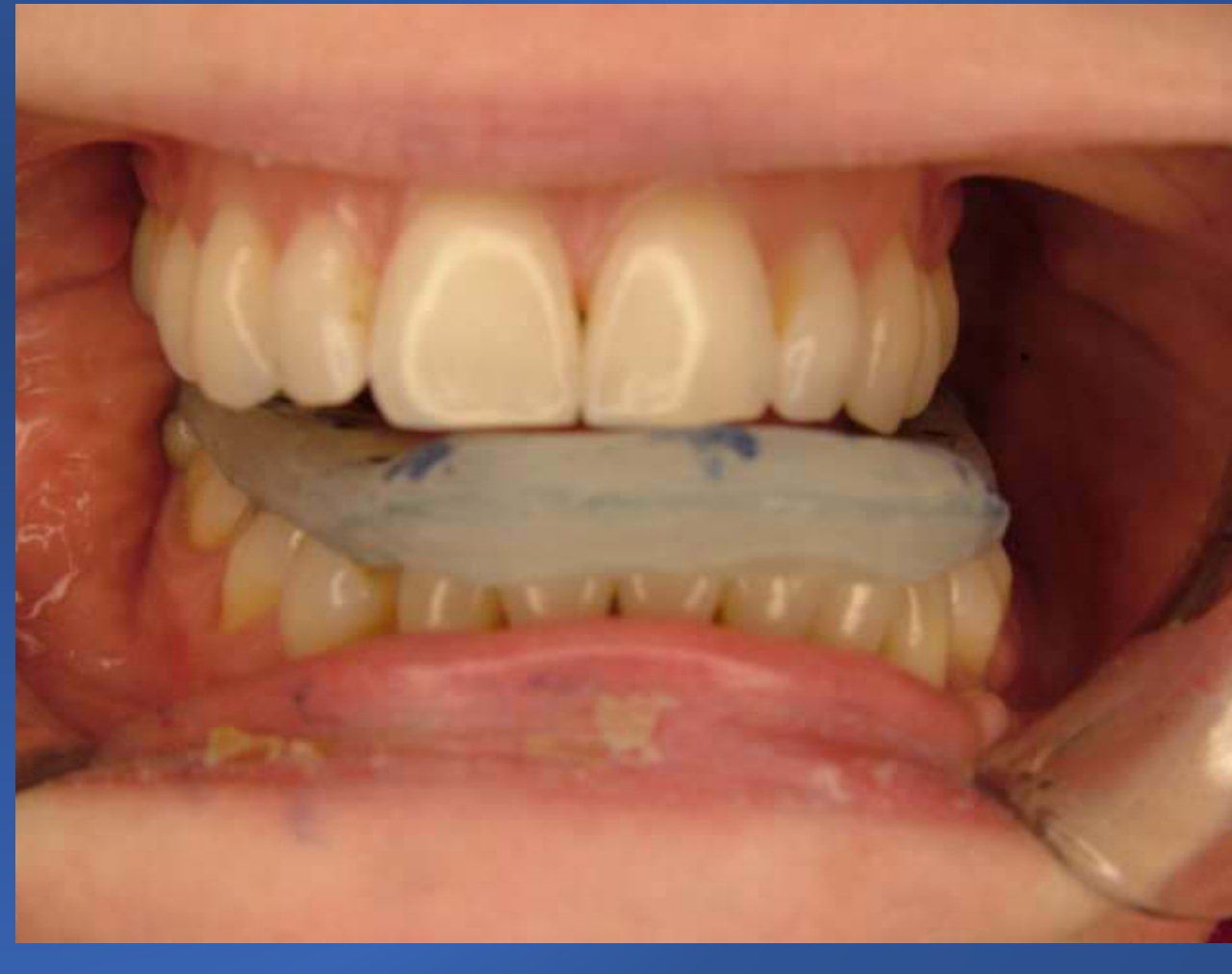
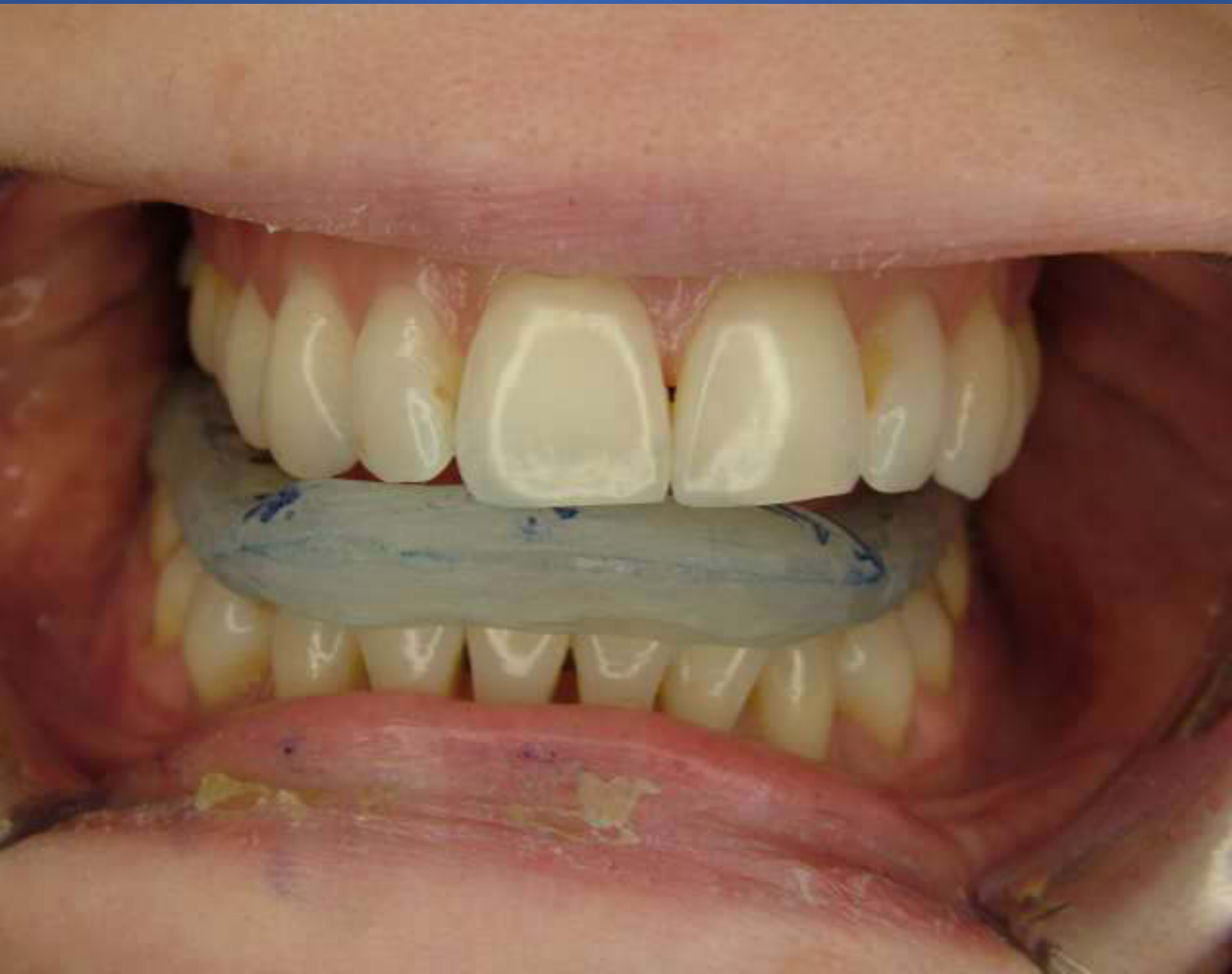
TMA, relined and adjusted in the mouth

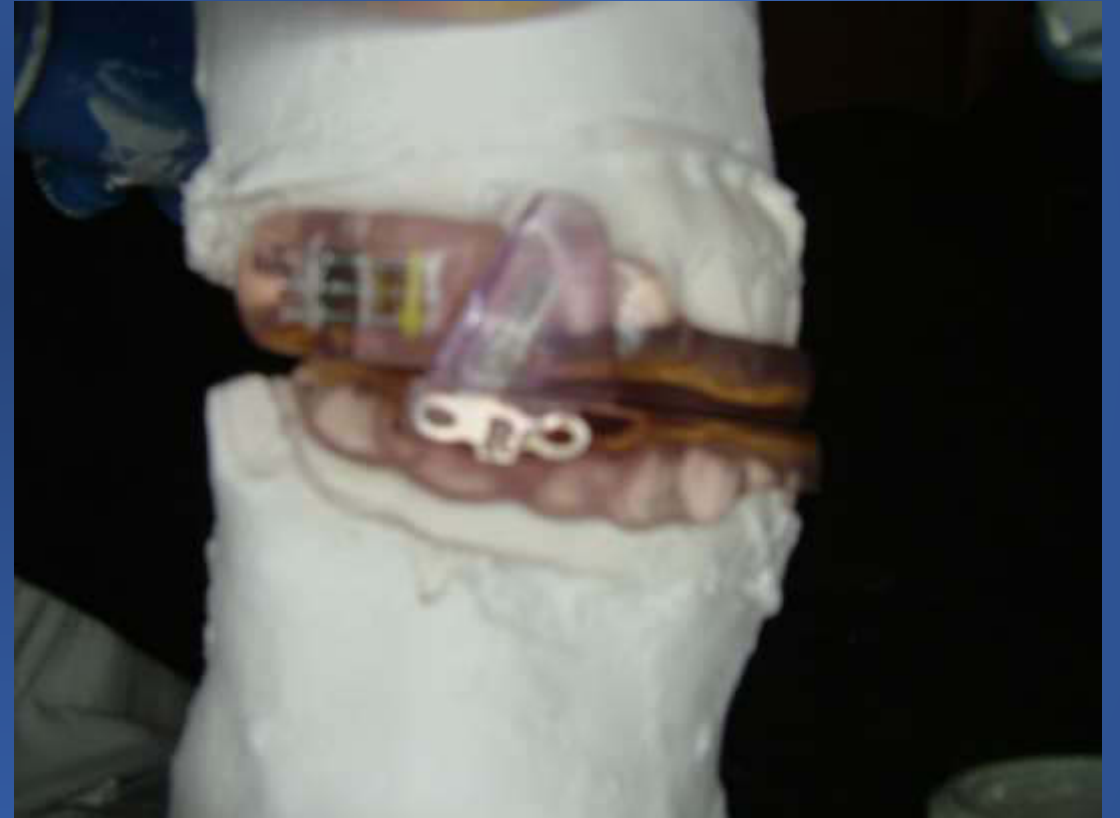

After 12 hours overnight , no fitting when Hyoid challenged, and has seen marked improvement in stability. Awaiting 2nd adjustment TMA and continuing AO treatment

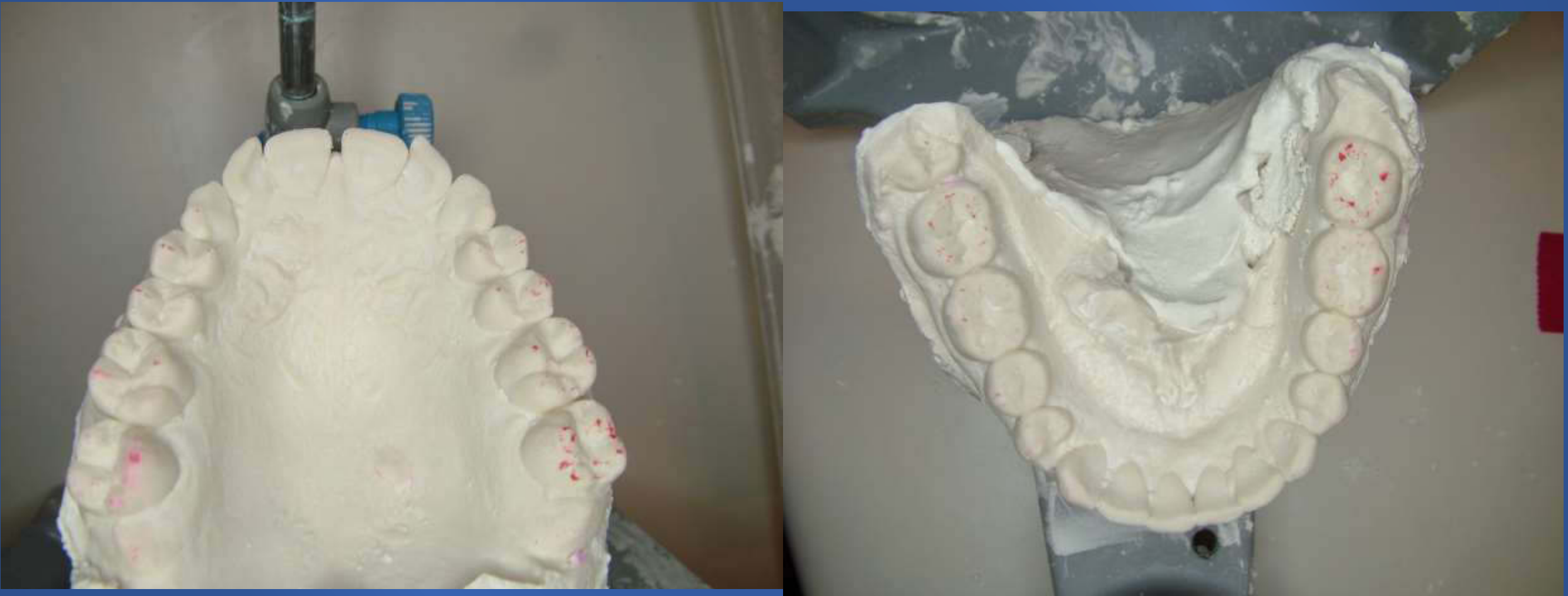Holly, lateral excursions restored on Anterior Guidance



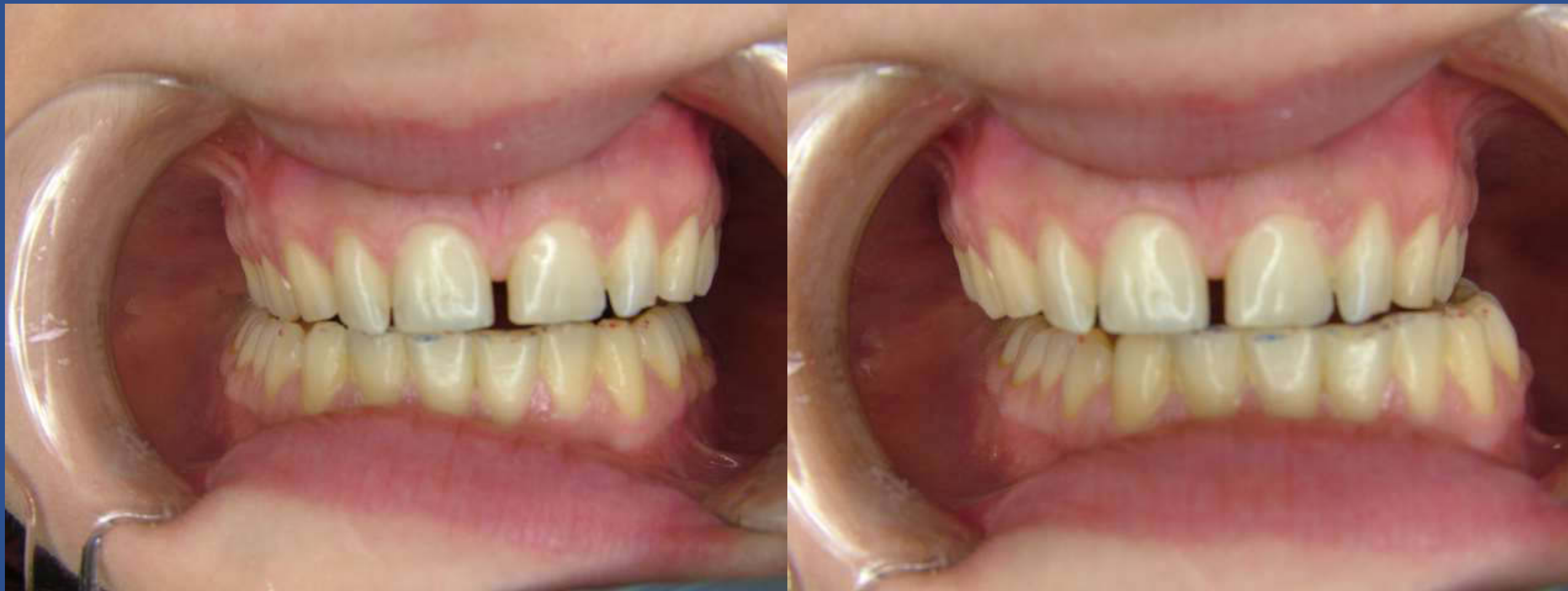SLEEP APPLIANCE, cause of CCJ distress EDS patient



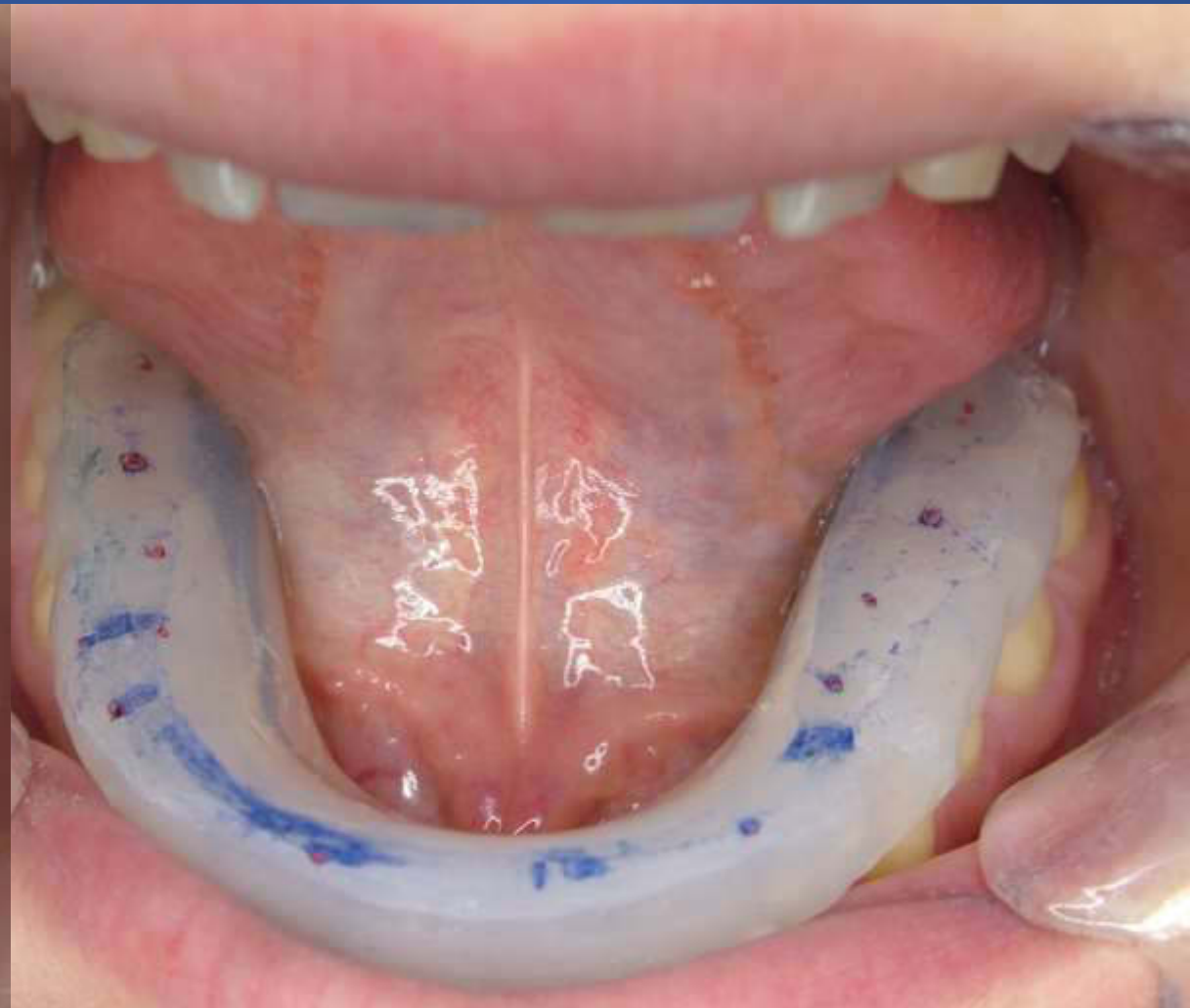
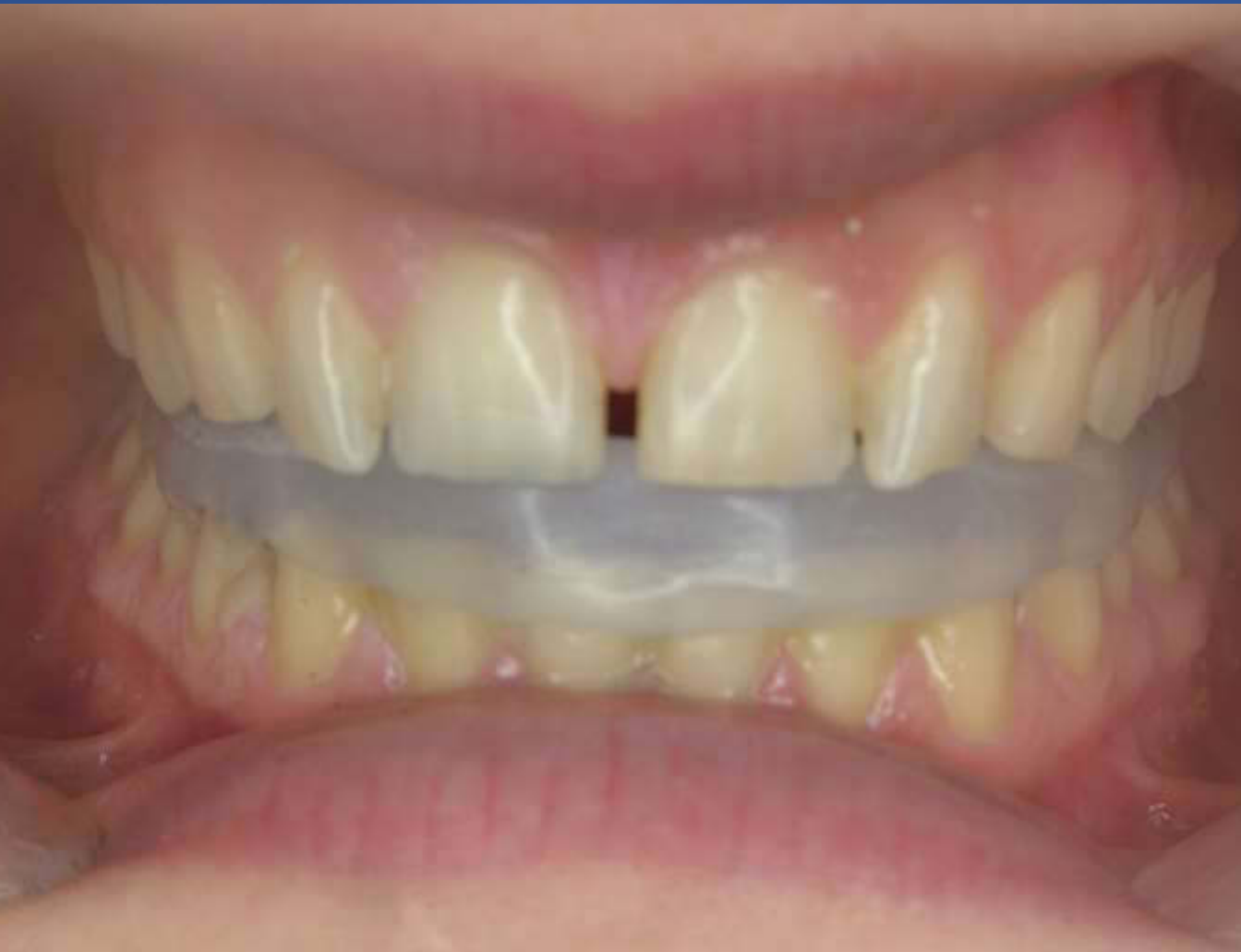SLEEP APPLIANCE, cause of acute distress EDS patient



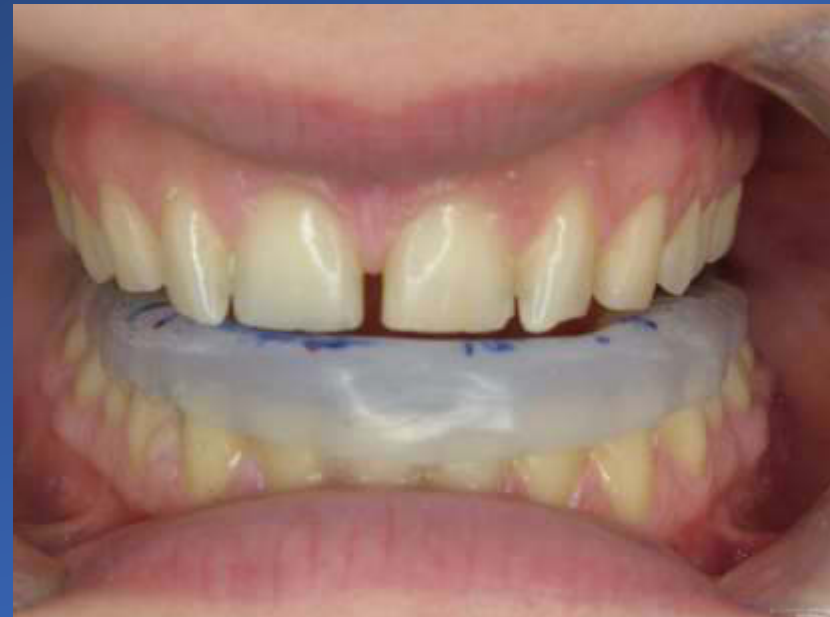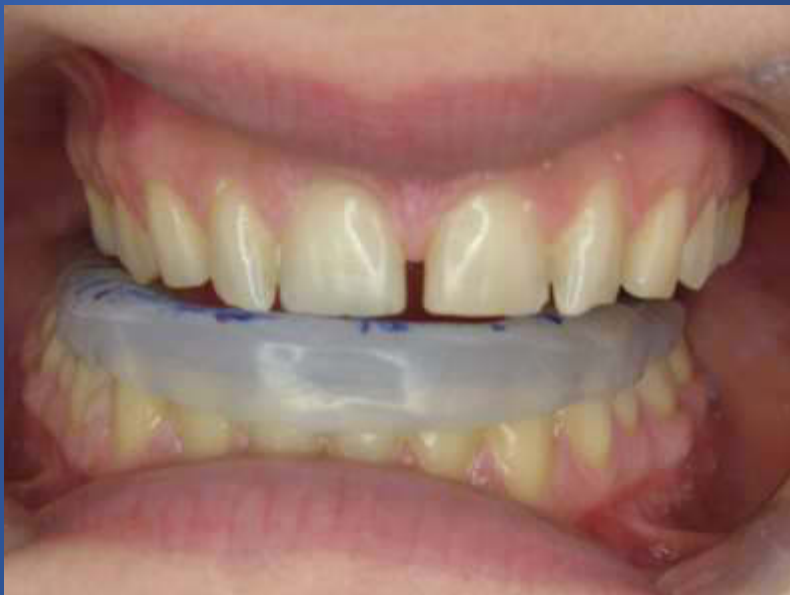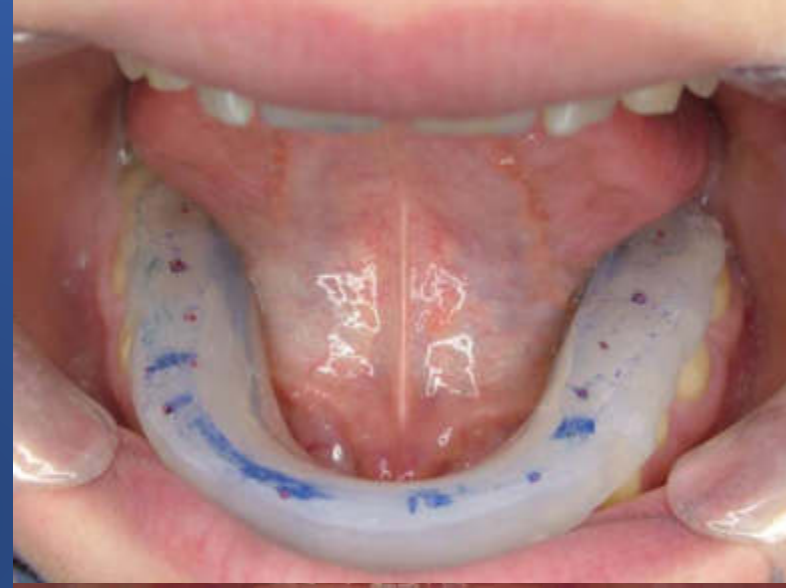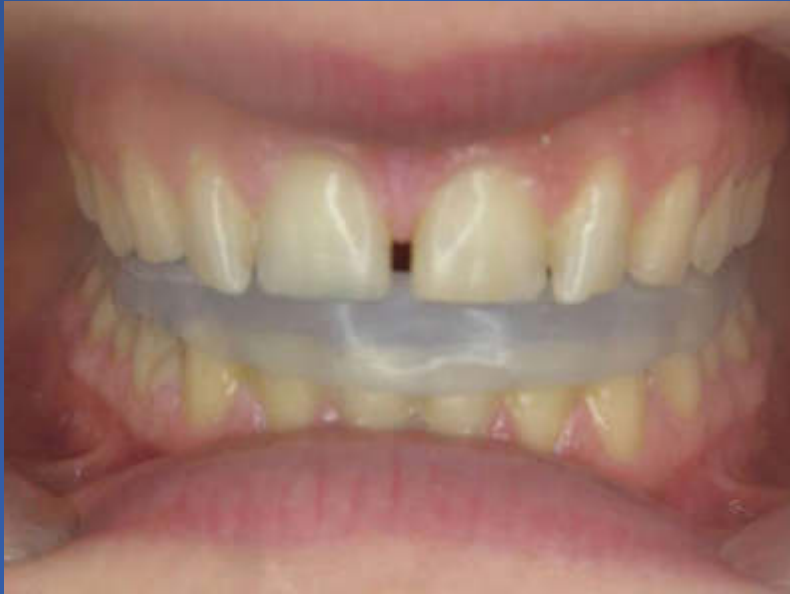SLEEP APPLIANCE, cause of acute distress EDS patient



TMA ADJUSTED TO GIVE SMOOTH SHALLOW GUIDANCE
AND EVEN POSTERIOR TOOTH CONTACT IN CRO



The TANNER APPLIANCE A CLIP-ON ADJUSTABLE PERFECT BITE



In Conclusion

- Centric Relation mounted models are an essential record to understanding dental occlusal function
- Occlusal Parafunction can cause upper cervical dysfunction, as well as CMD, and affect sleep and should be recognized and treated
- A healthy mouth is essential for a healthy patient

Formula to achieve and maintain a healthy mouth

- AVOID REFINED SUGAR
 - GOOD ORAL HYGIENE
 - CHECK ORTHOPAEDIC JAW DEVELOPMENT AGE 8-12
 - AVOID TRAUMA , RTAs and HORSES
-
- IF YOU HAVEN'T MANAGED THESE, GET YOUR BITE FIXED WITH A TANNER APPLIANCE AND EQUILIBRATION, AND SEE A GOOD AO PRACTITIONER

